

CASE 9

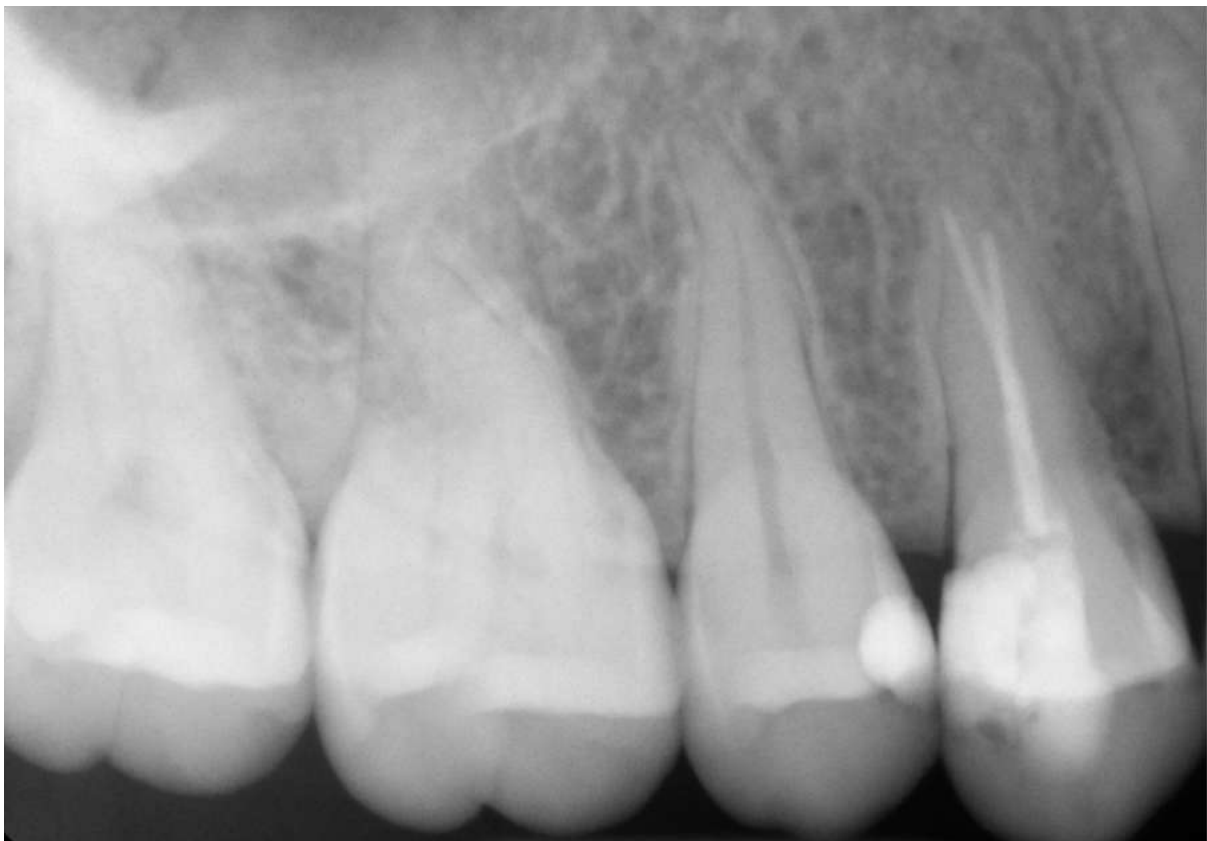SEX: Female AGE: 40 years old NAME G.R..

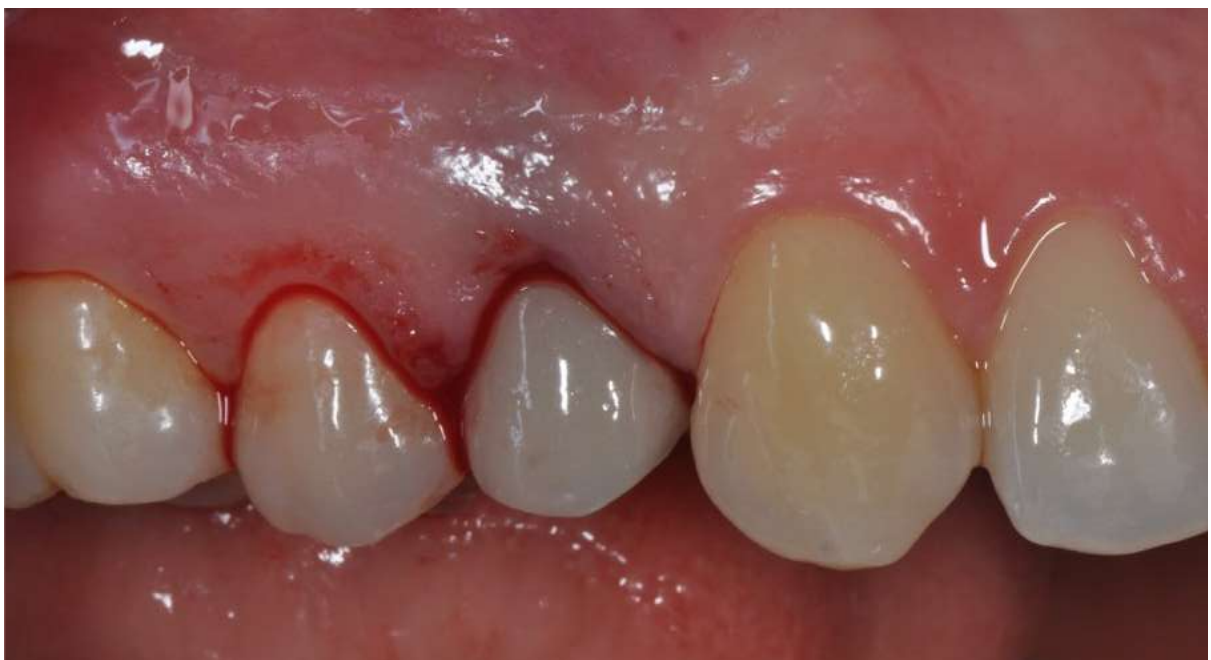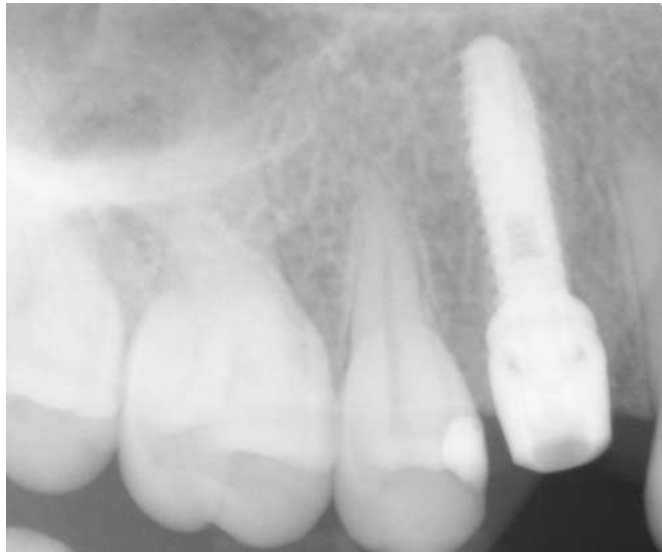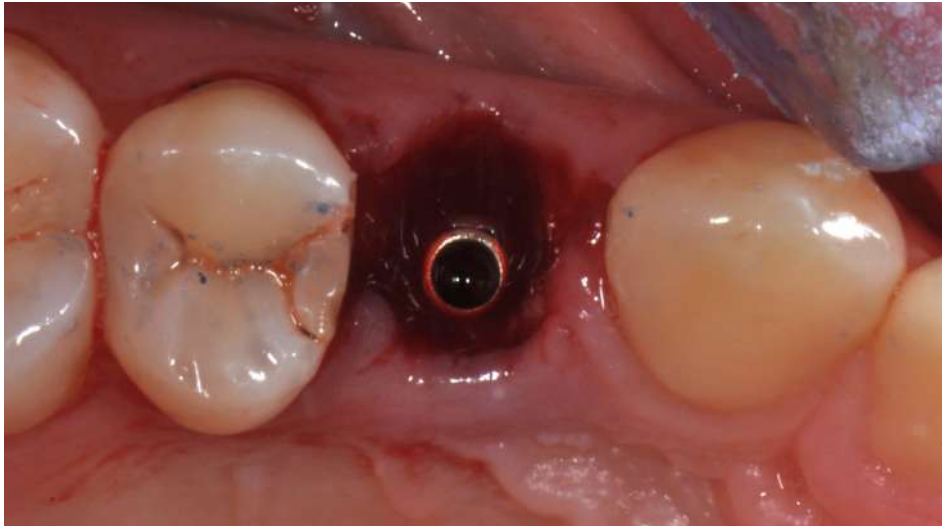
SYSTEMIC ANAMNESIS: negative

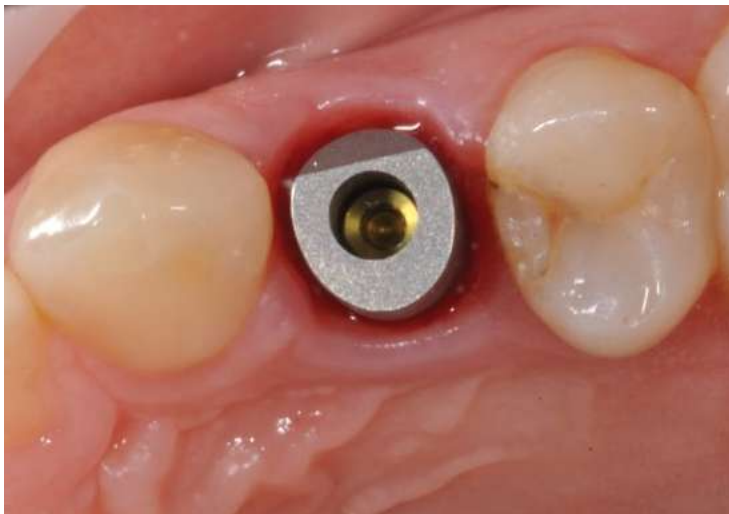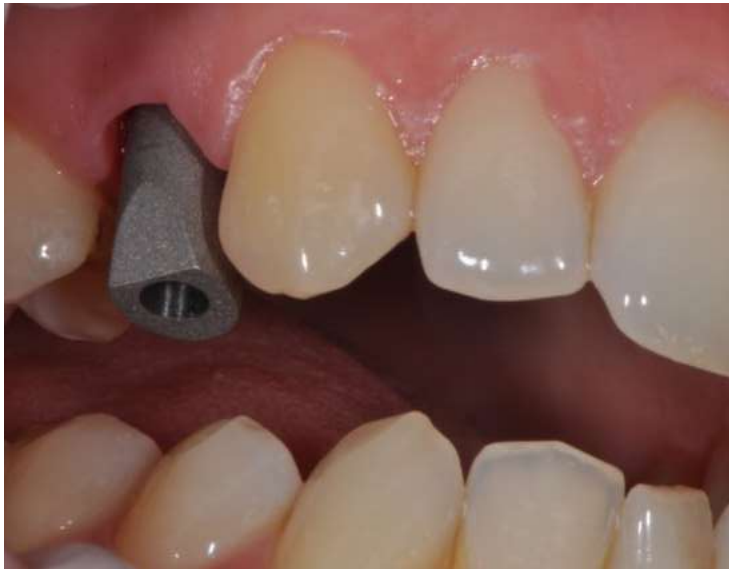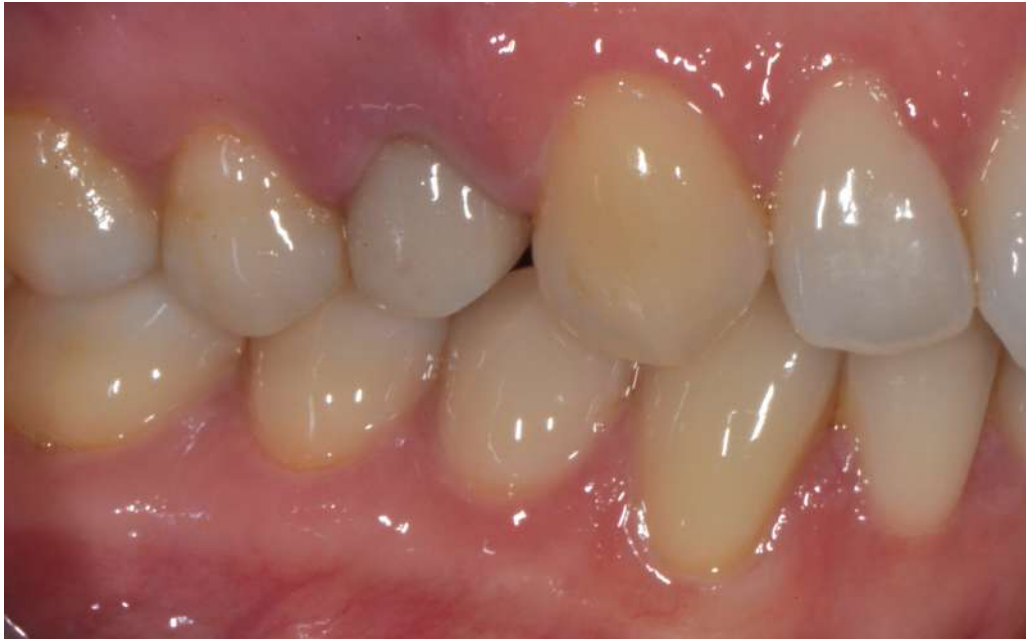SMOKING: nothing DRUGS TAKEN: nothing

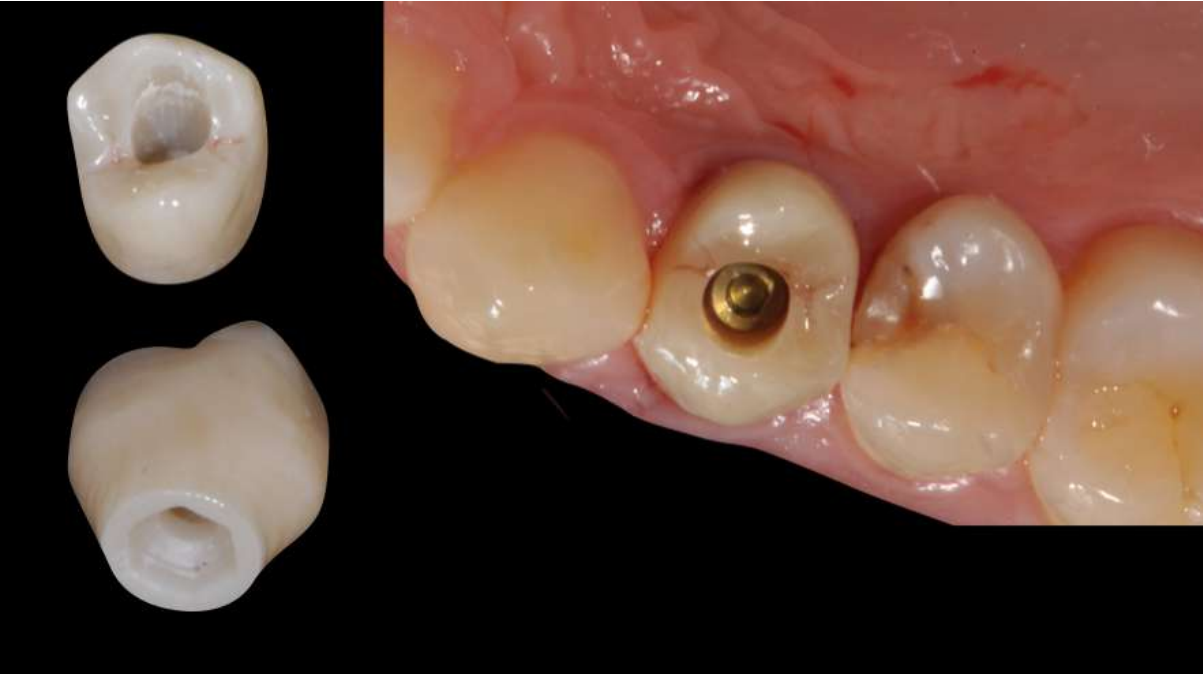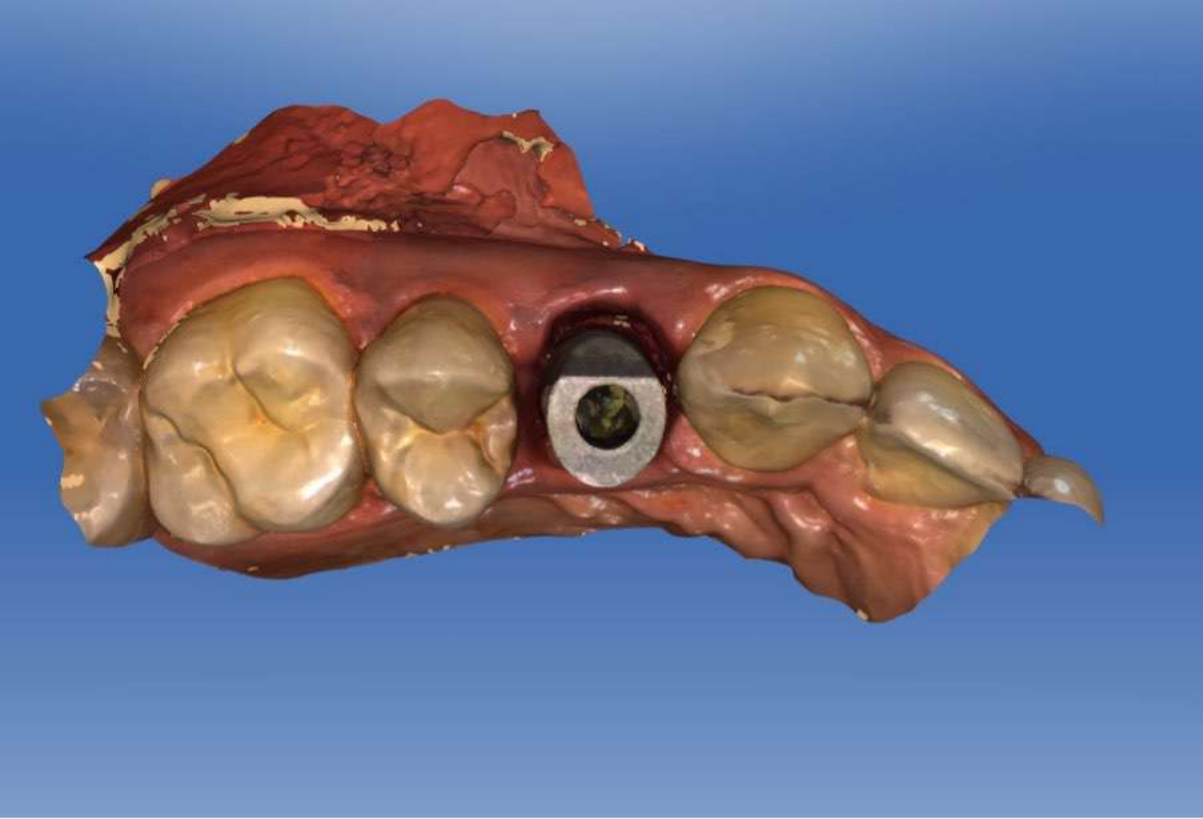
DIAGNOSIS: tooth fracture of 14

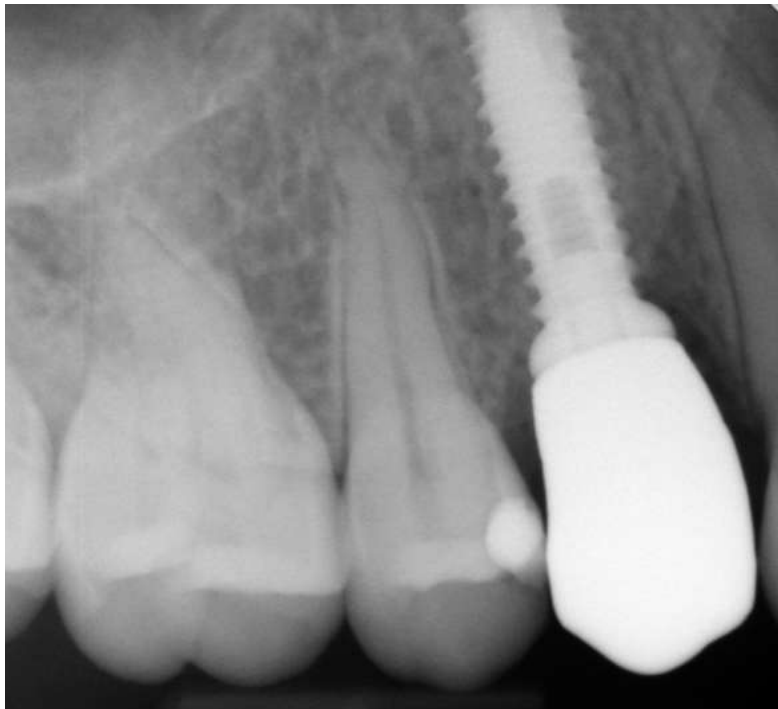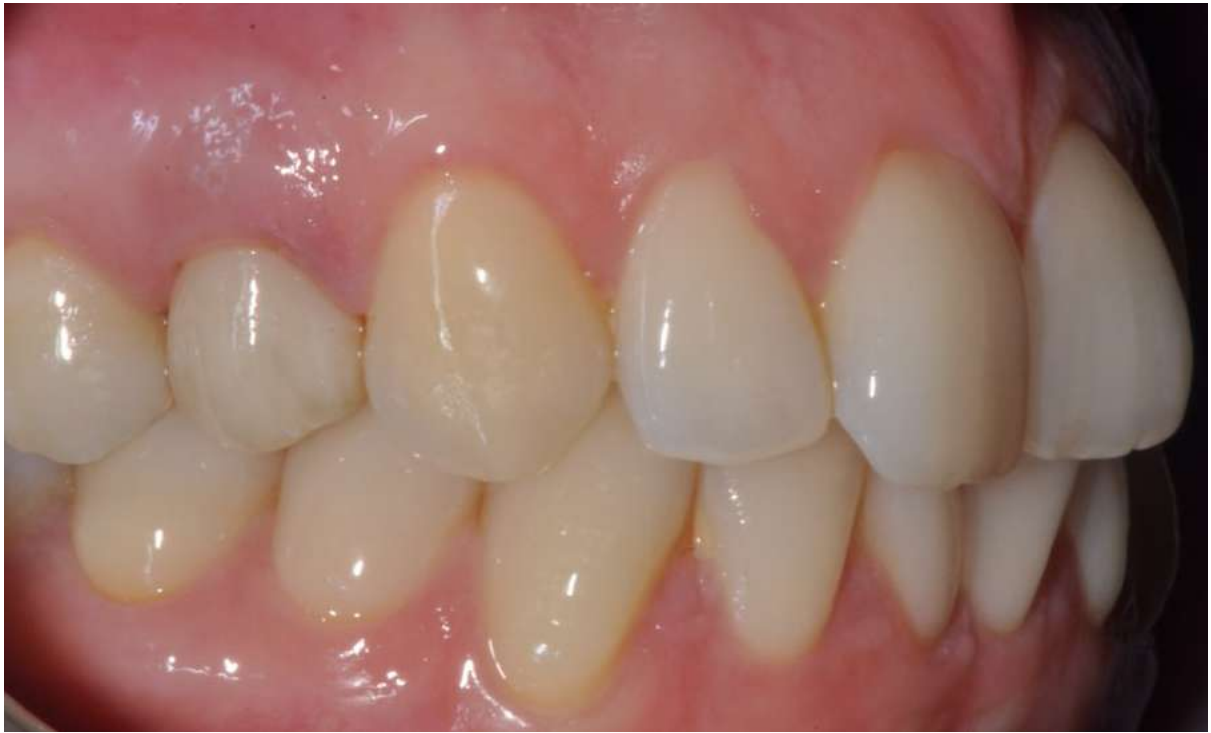THERAPY: immediate post-extractive implant of 14 and immediate screwed temporary crown. After 4 months of healing, a zirconium-ceramic screwed crown was placed. Impression with intraoral digital scanner (Cerec - Sirona).











Follow up at 2 years

