

## CASE 8

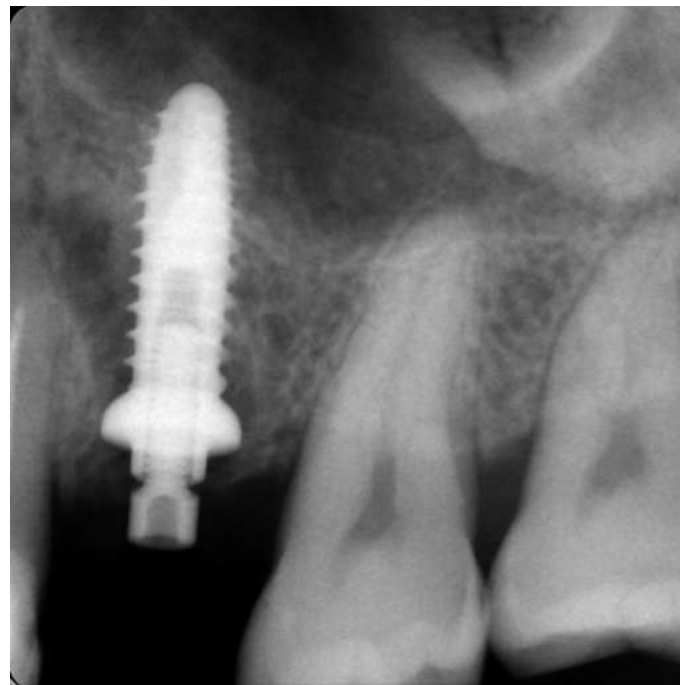
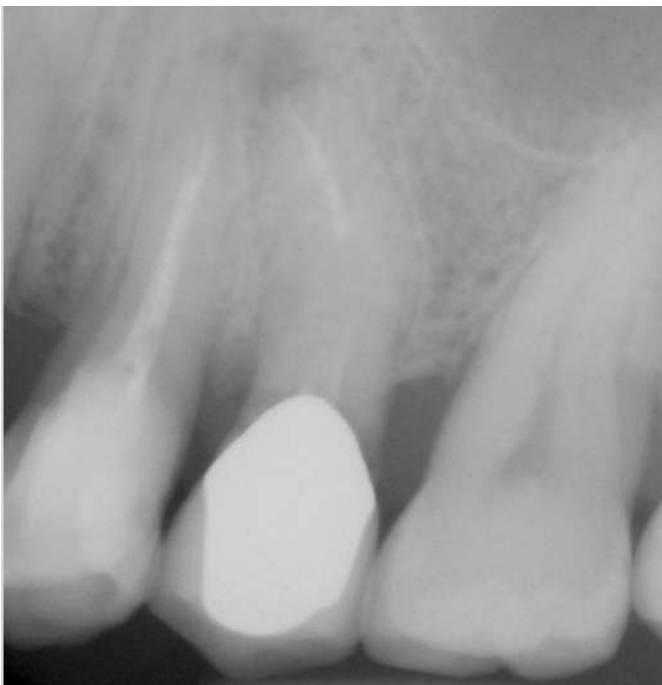SEX: Male AGE: 52 years old NAME M.B.

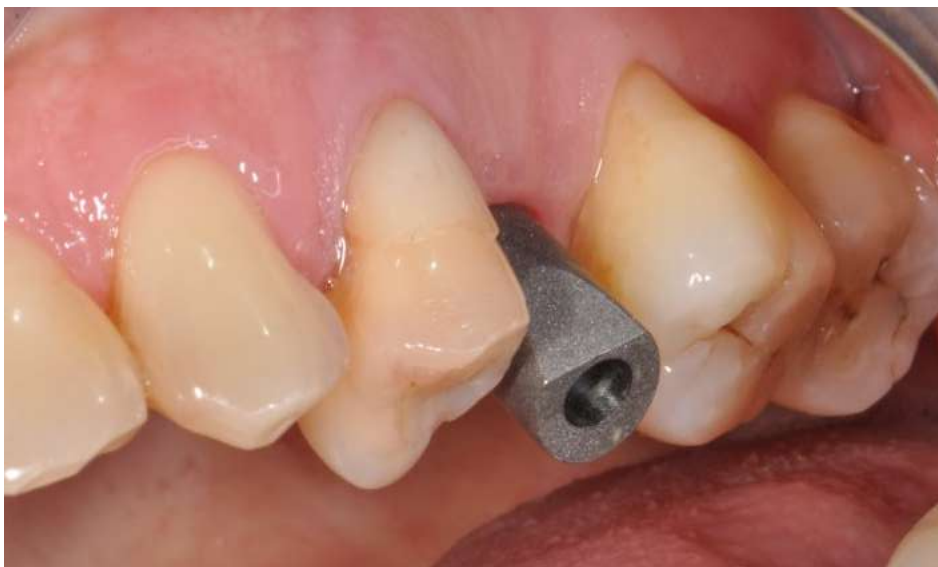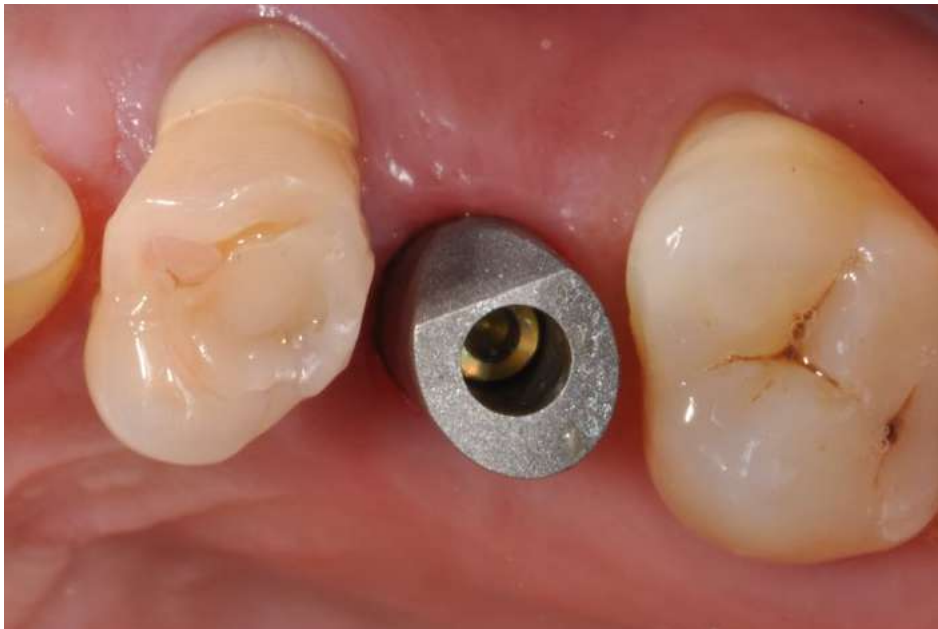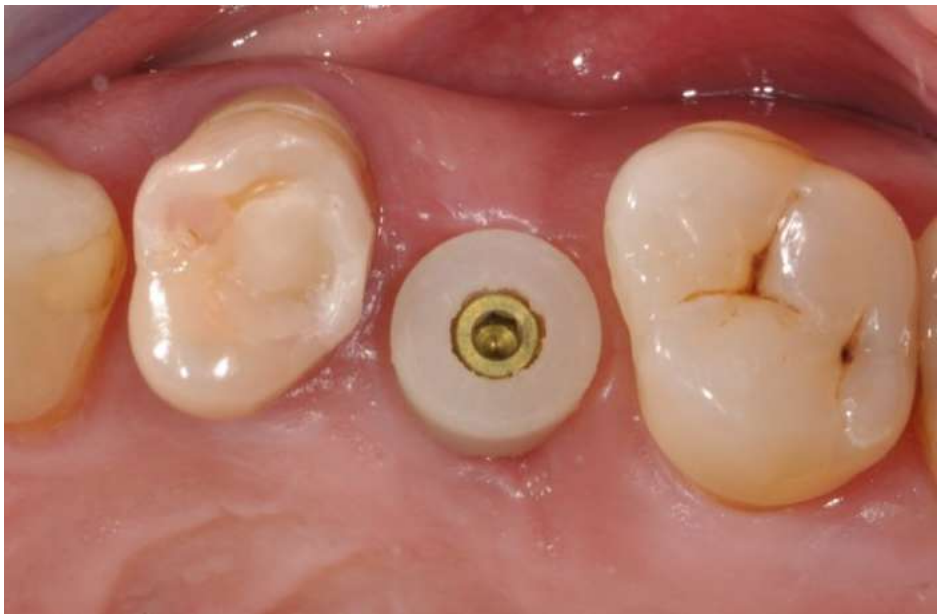SYSTEMIC ANAMNESIS: negative

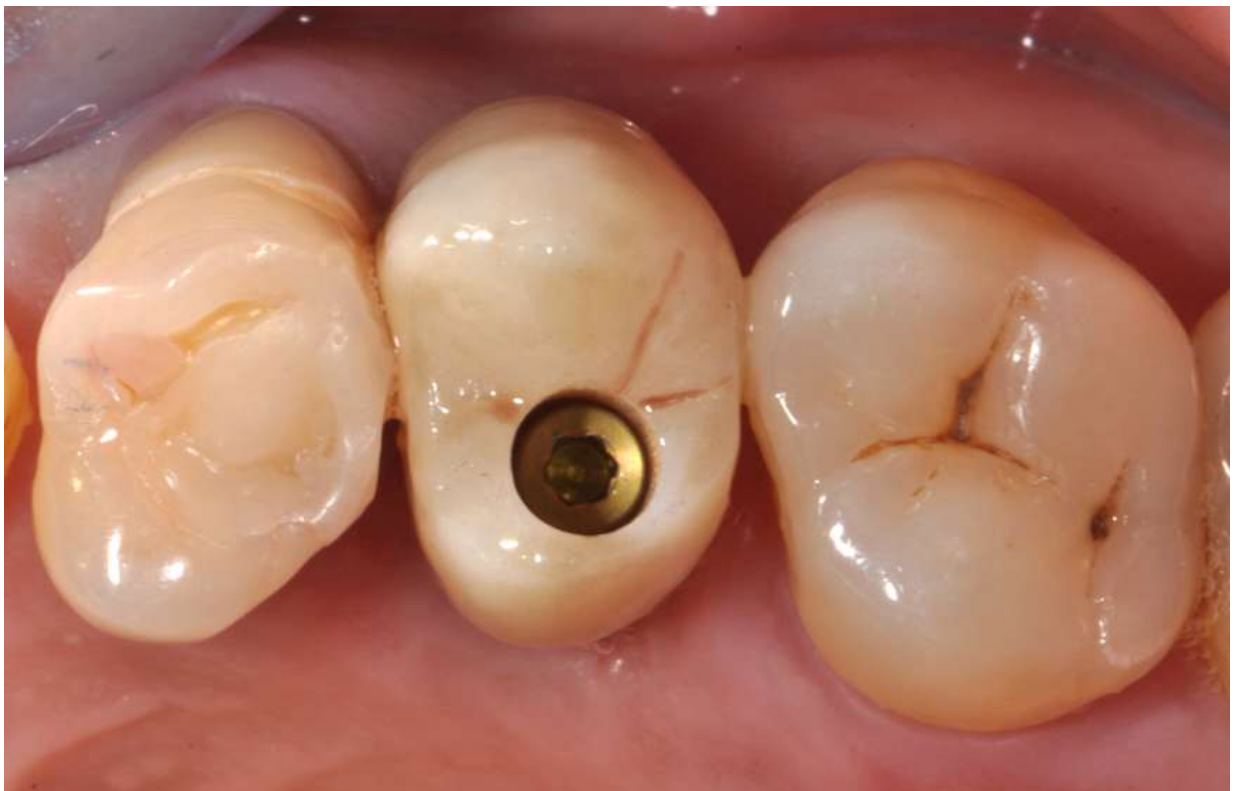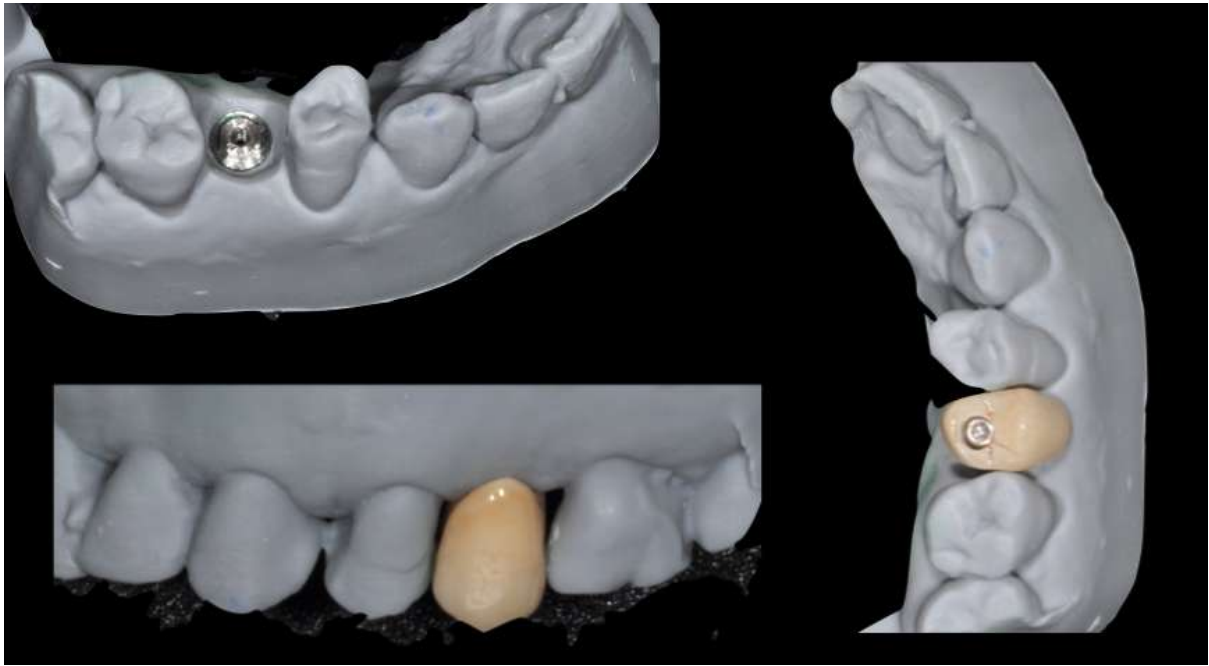
SMOKING: 10 cigarettes/day DRUGS TAKEN: nothing

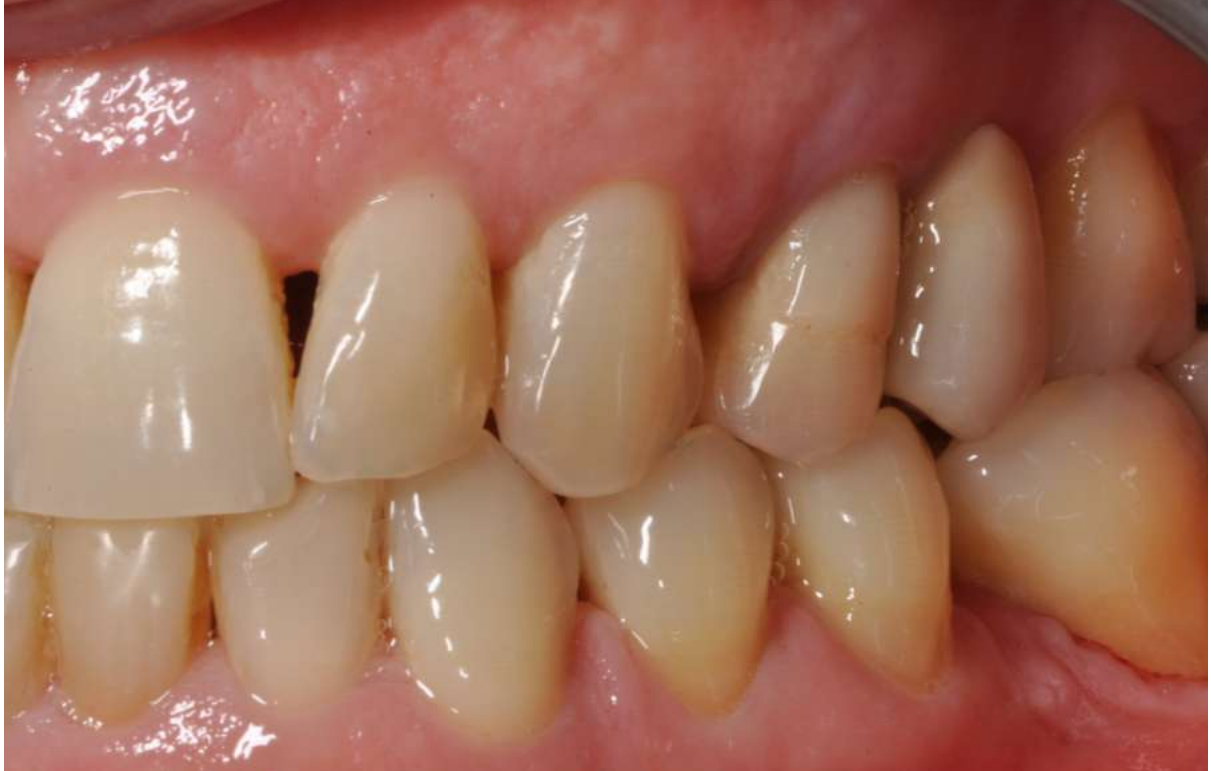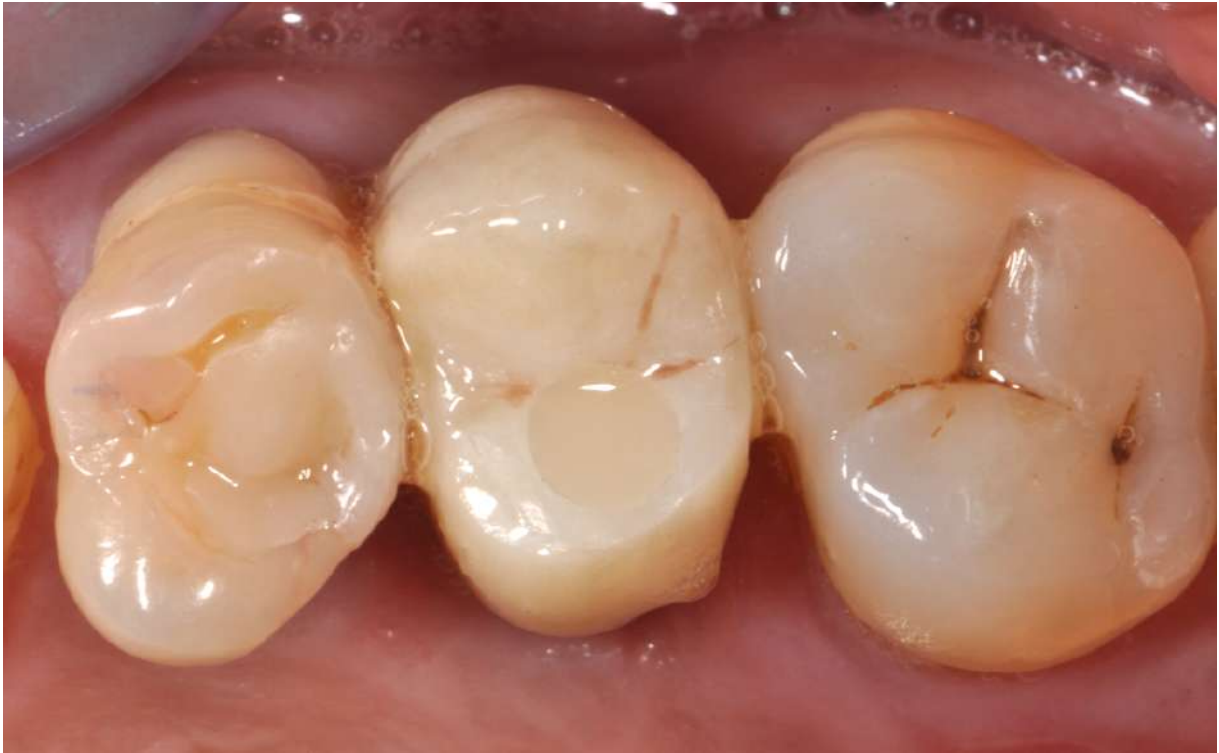DIAGNOSIS: endodontic disease of 25

THERAPY: immediate post-extractive implant of 25 and after 4 months of healing with a caps, a zirconium-ceramic screwed crown was placed.









Follow up at 2 years

