

## CASE 7

SEX: Female AGE: 48 years old NAME P.I..

SYSTEMIC ANAMNESIS: negative

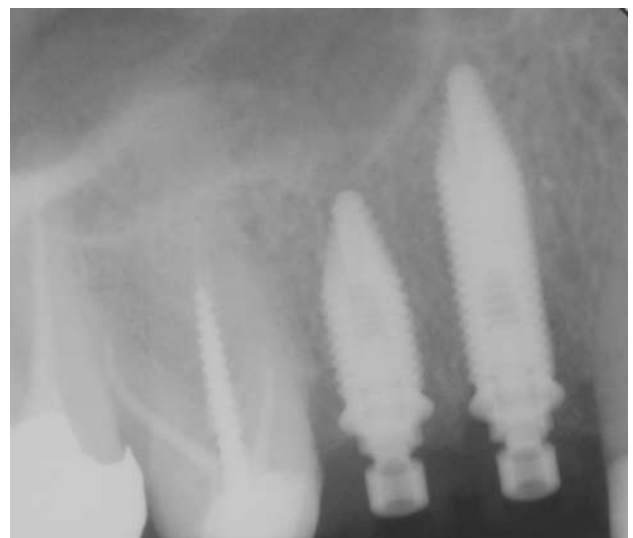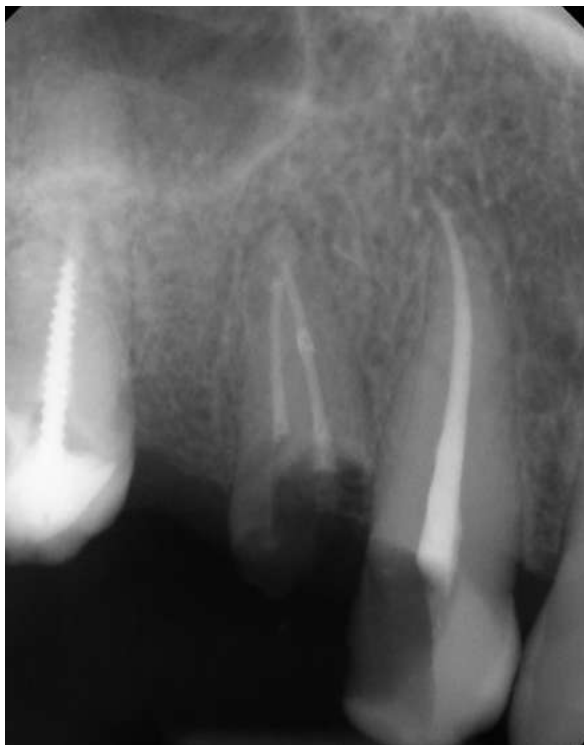SMOKING: nothing

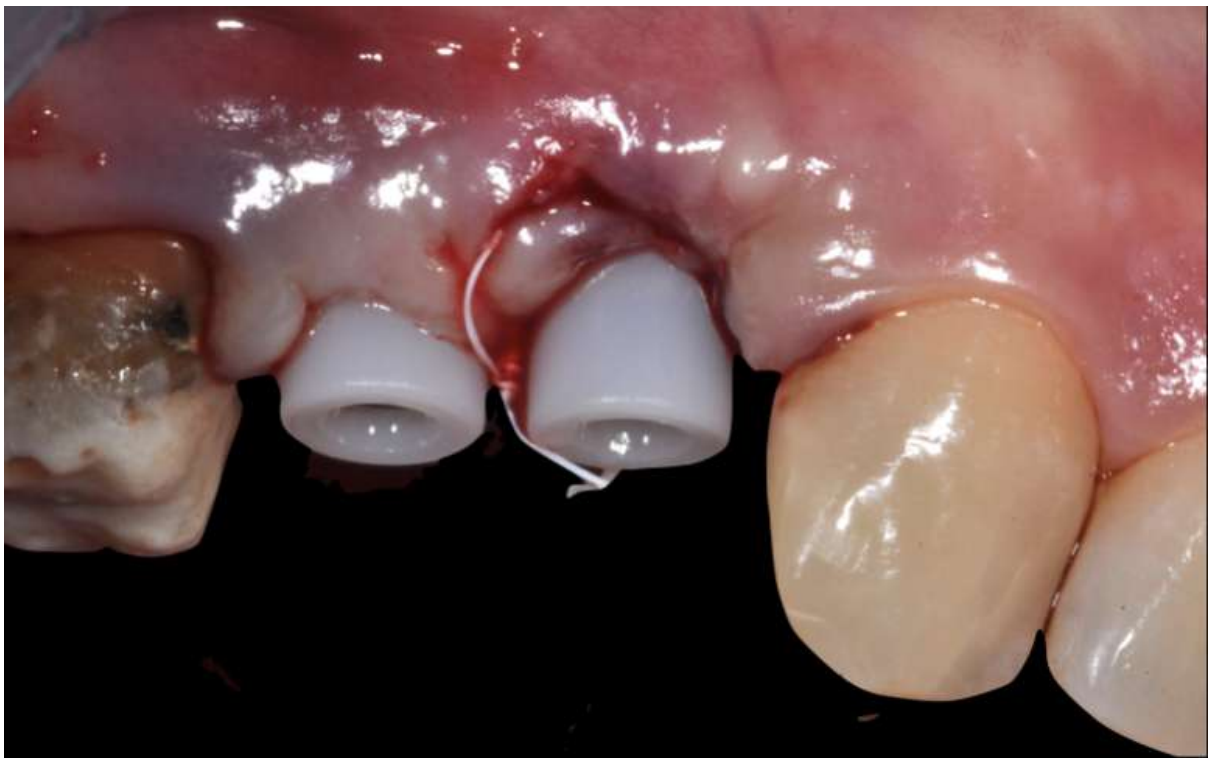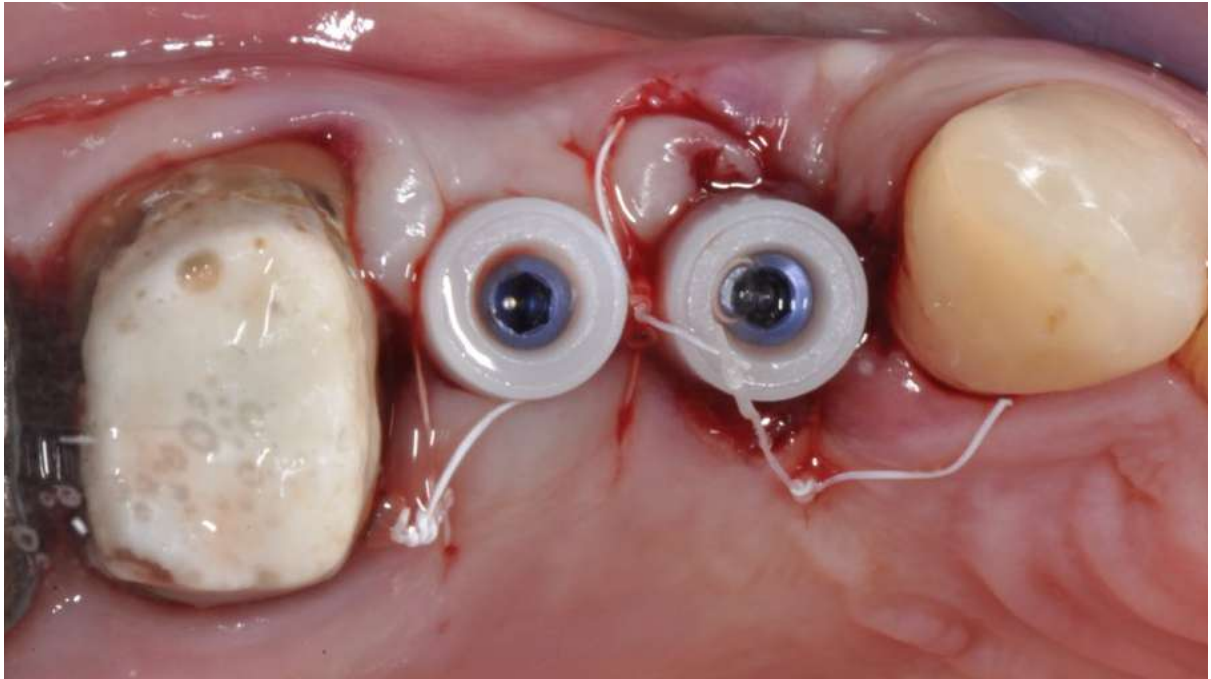
DRUGS TAKEN: nothing

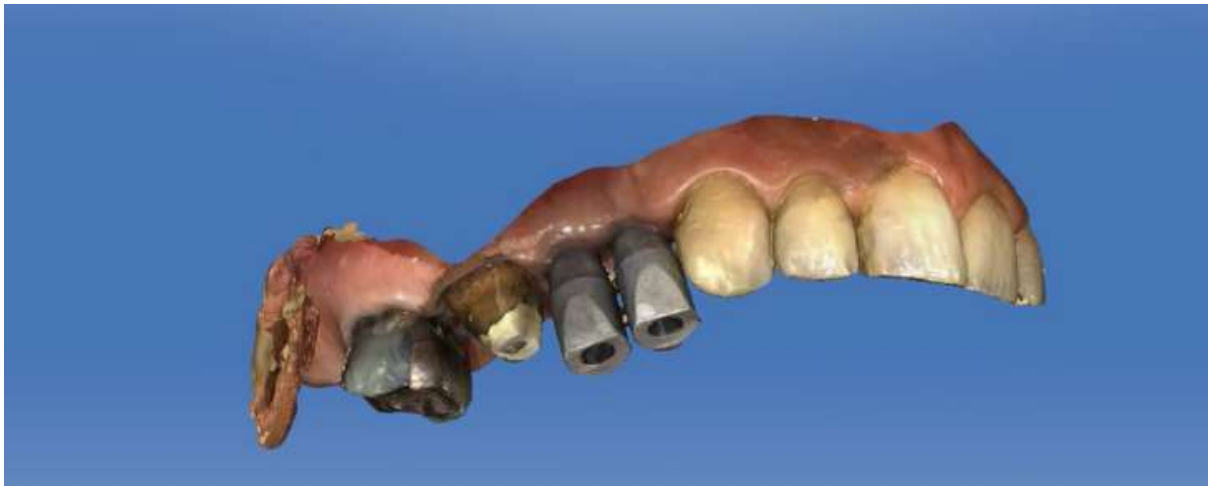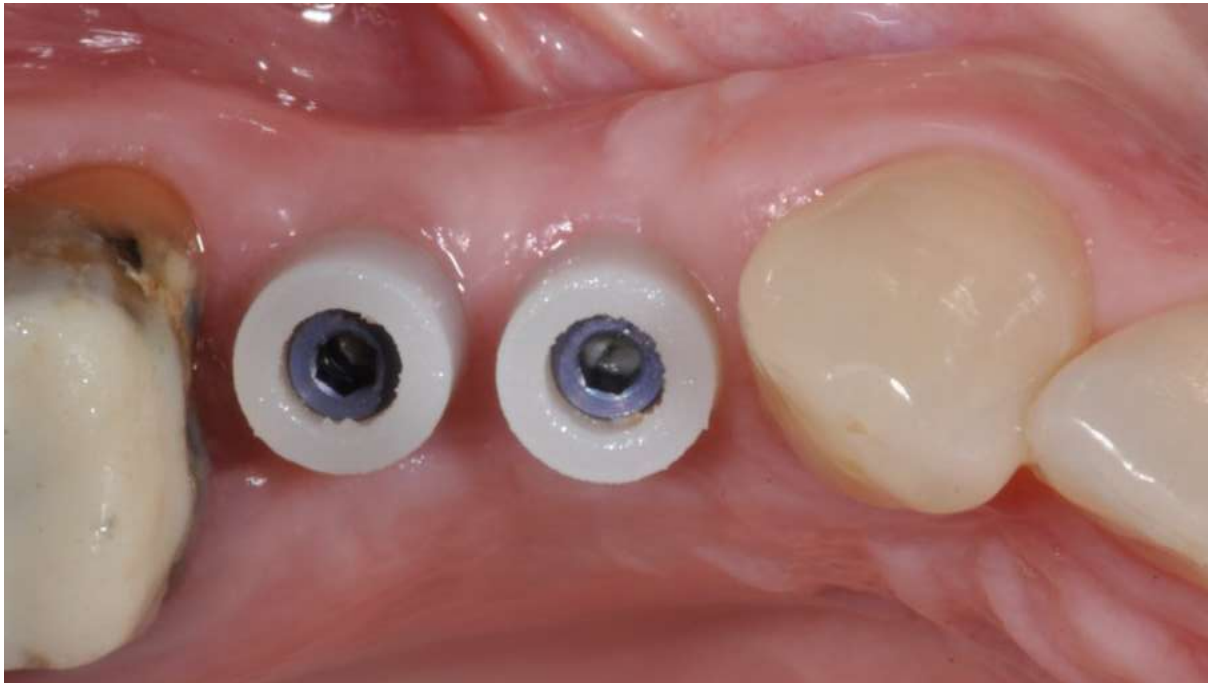
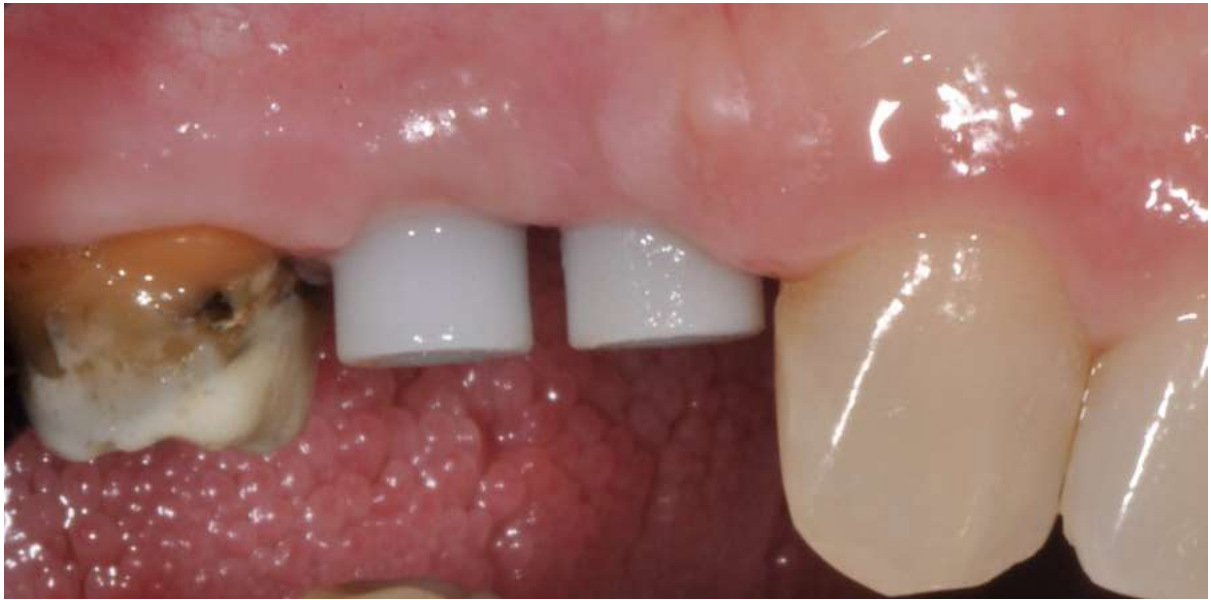DIAGNOSIS: lost tooth 14 and edentulism of 15

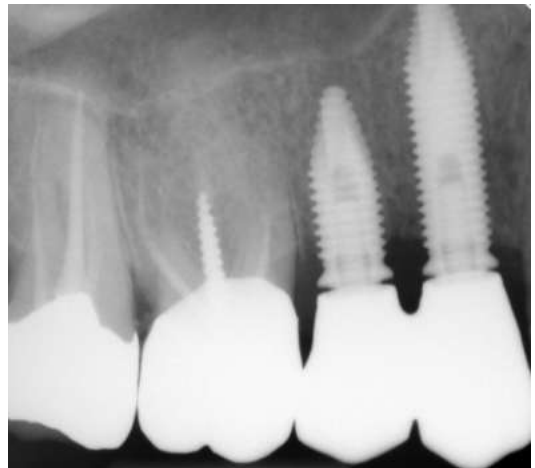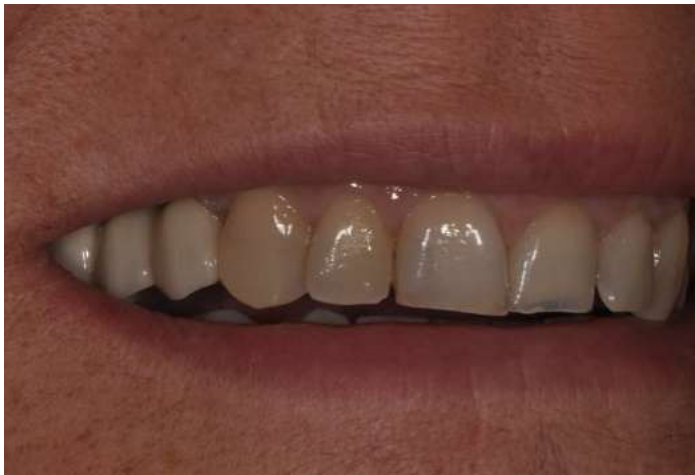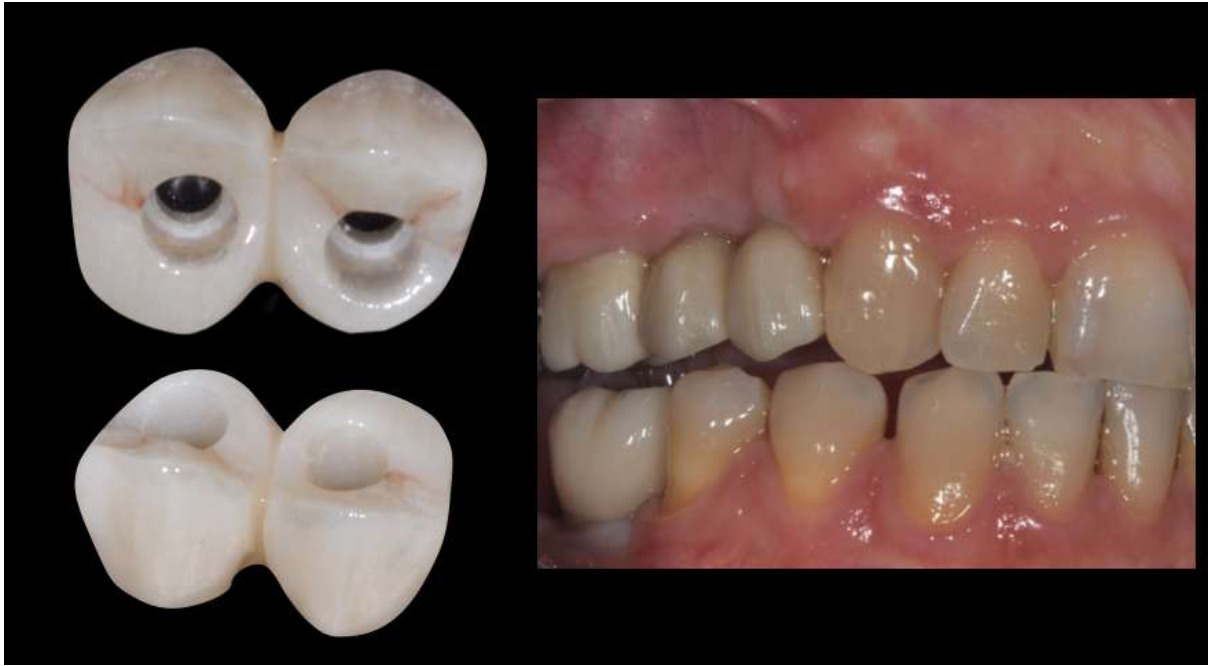THERAPY: post-extractive implant of 14 and implant of 15.

After 4 months of healing with two caps, two zirconium-ceramic screwed crown was placed. Impression with intraoral digital scanner (Cerec -Sirona).









Follow up at 2 years

