

CASE 6

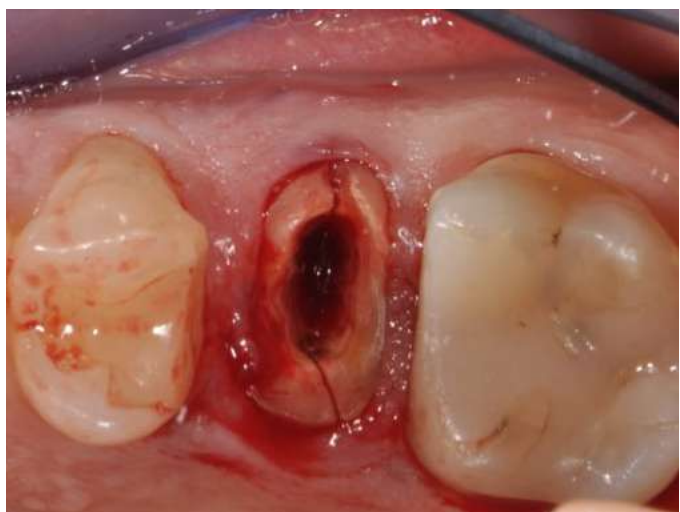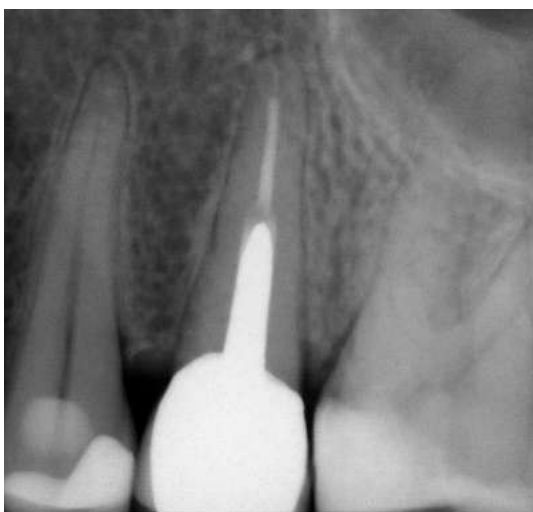SEX: Female AGE: 45 years old NAME M.A.

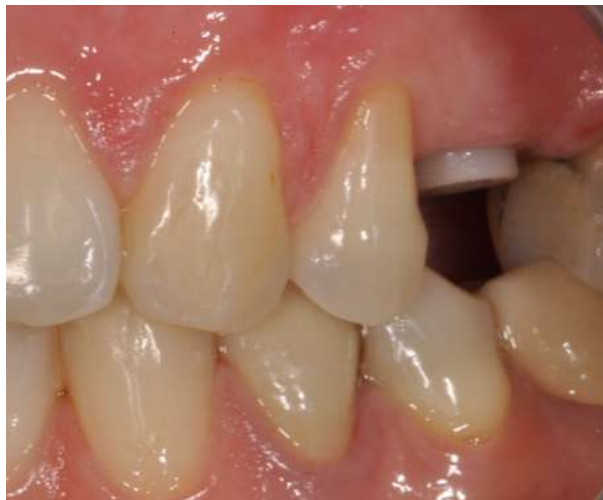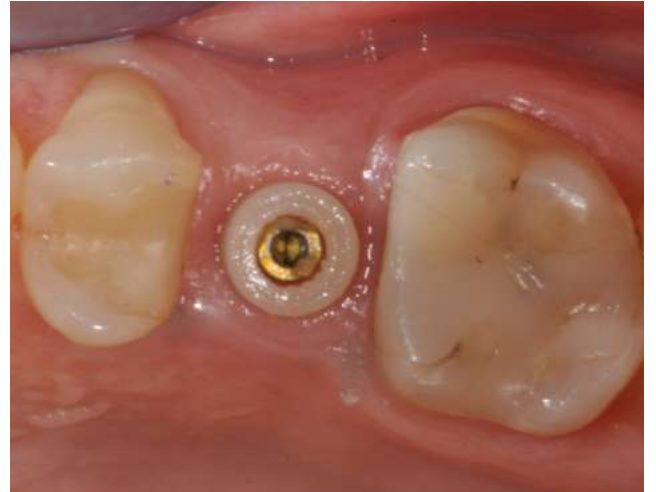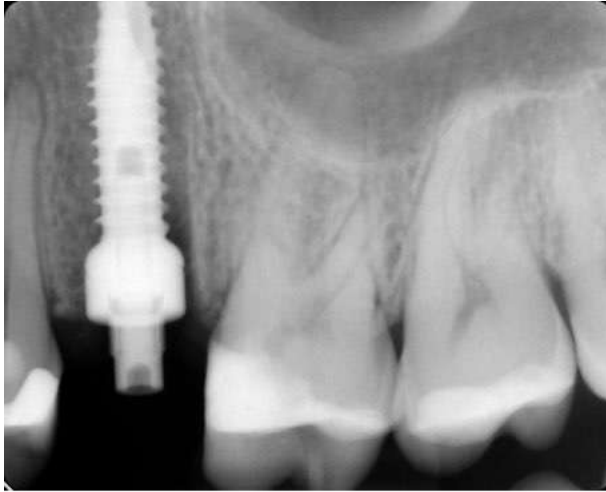
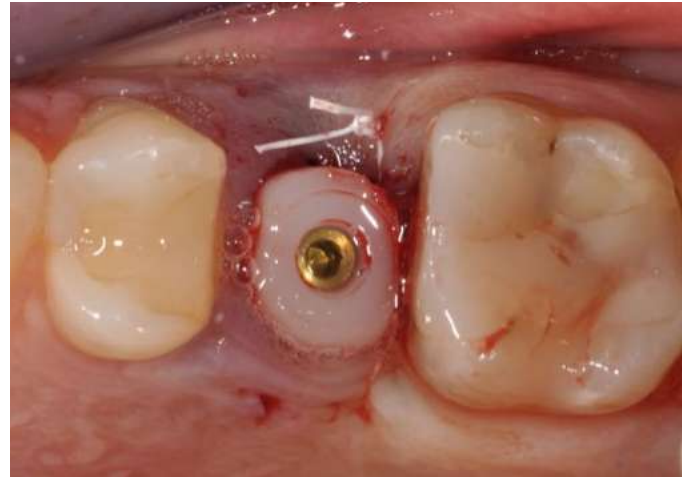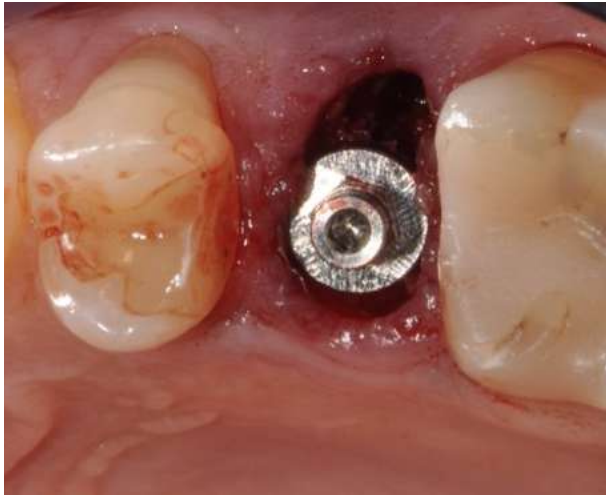SYSTEMIC ANAMNESIS: negative

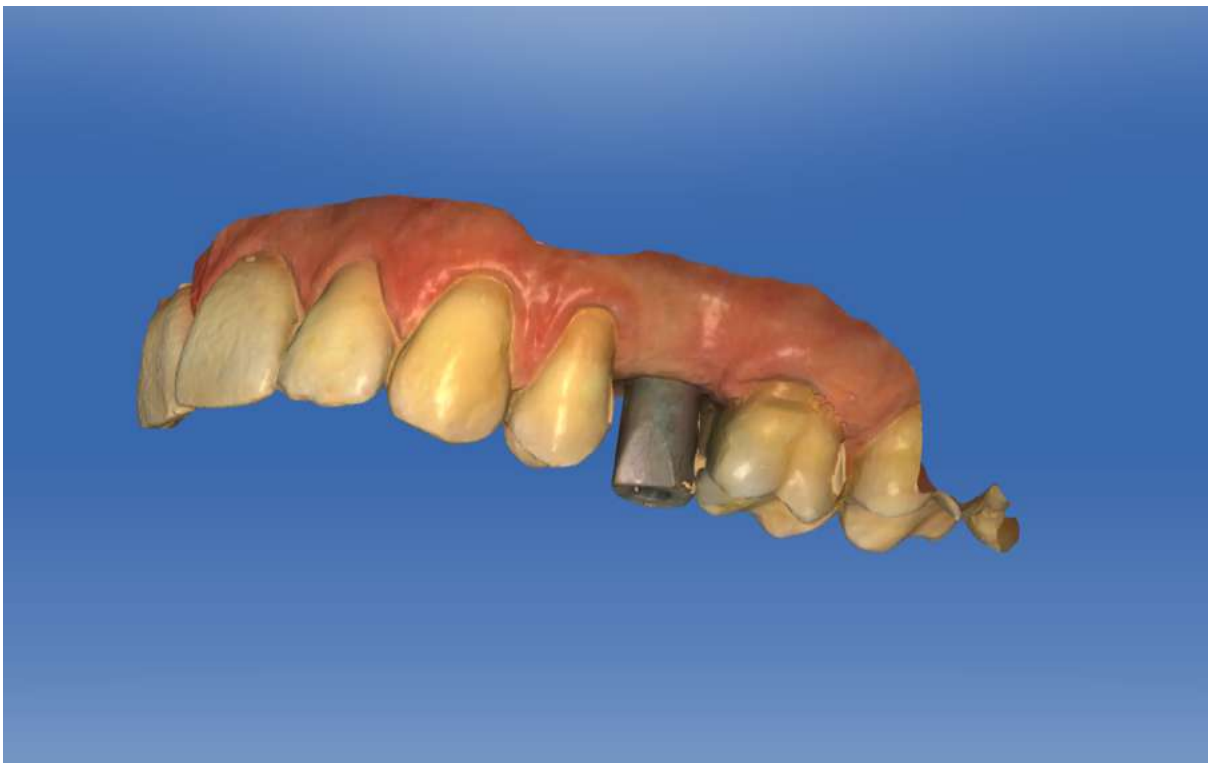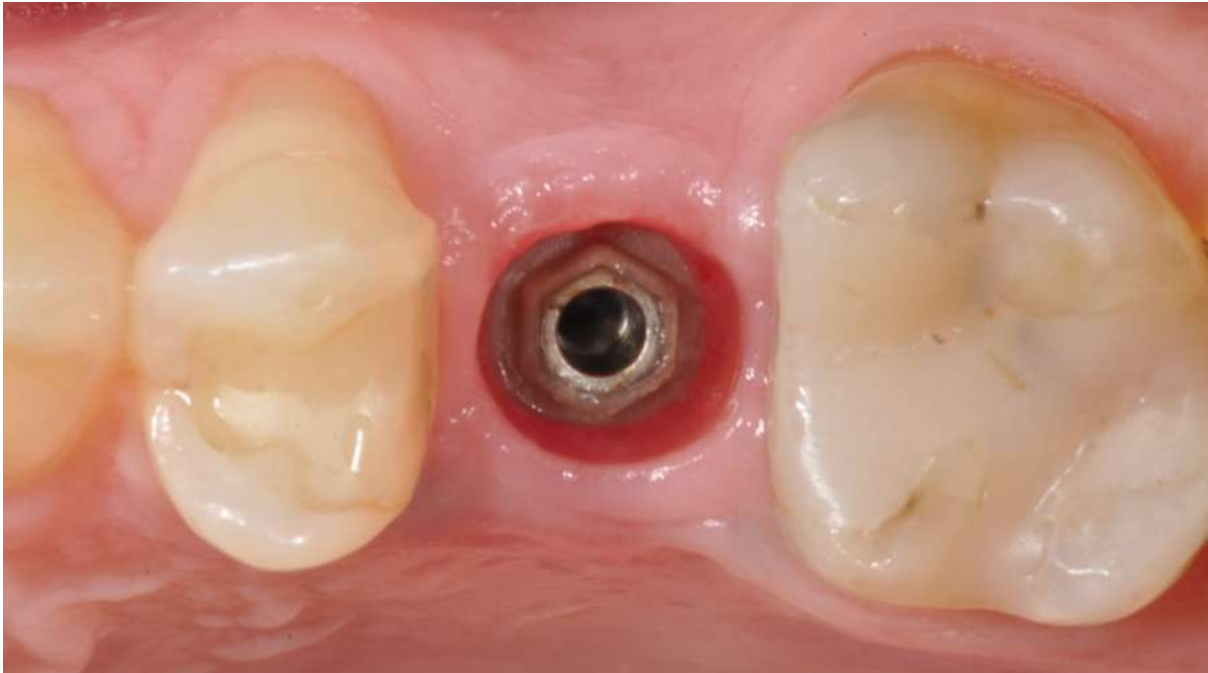
SMOKING: nothing DRUGS TAKEN: nothing

DIAGNOSIS: tooth fracture of 25

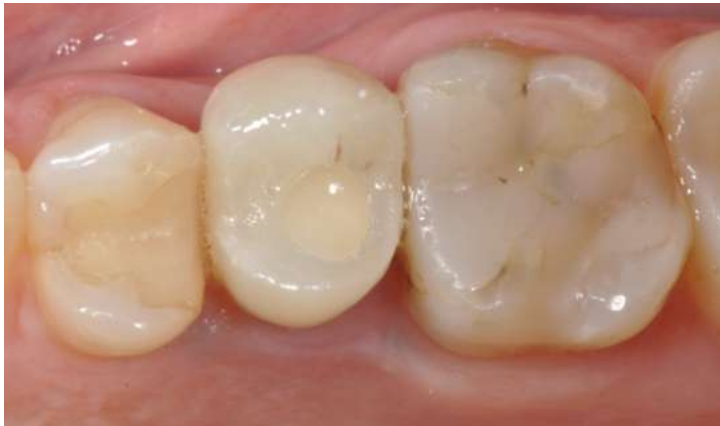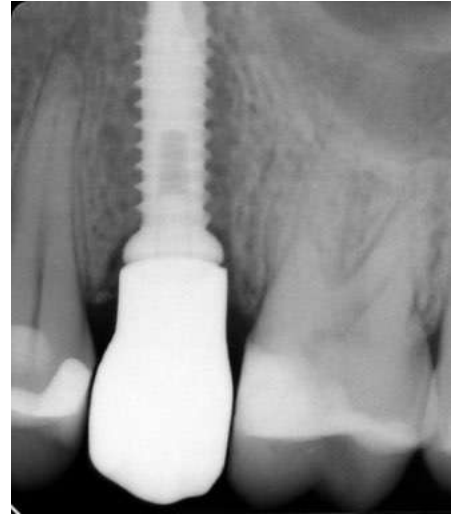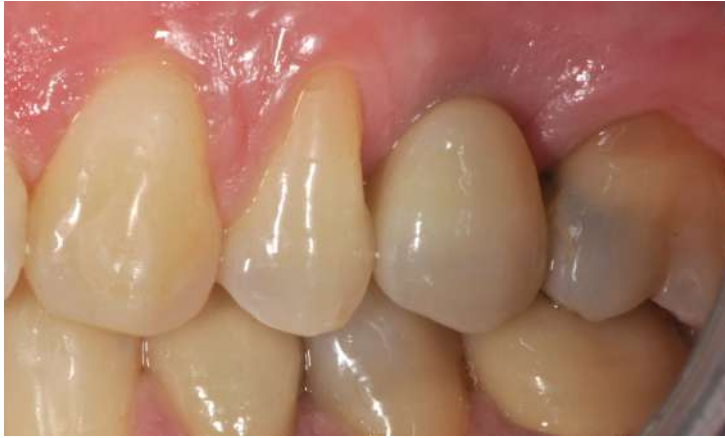THERAPY: extraction of 25 and immediate post-extraction implant was placed. After 4 months of healing with a caps, an impression with intraoral digital scanner (Cerec - Sirona) was taken and a zirconium-ceramic screwed crown was placed.







Impression with Intraoral Digital Scanner (Cerec - Sirona)



Follow-up at 1 years

