

CASE 3

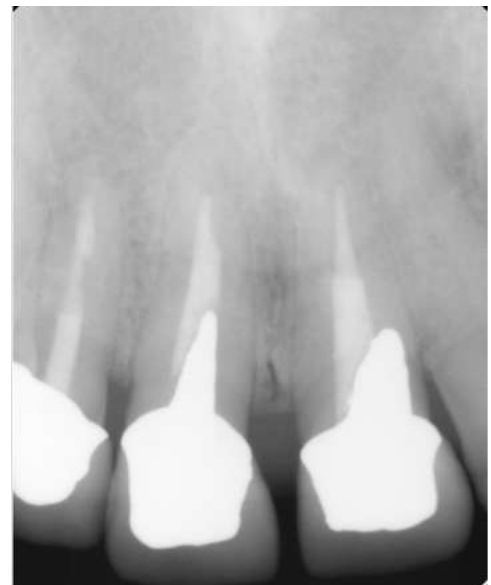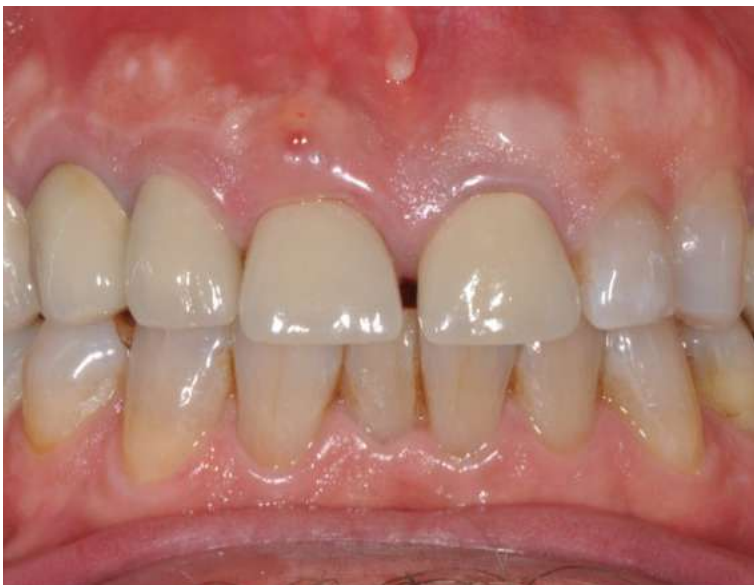SEX: Male AGE: 43 years old NAME: A.M.

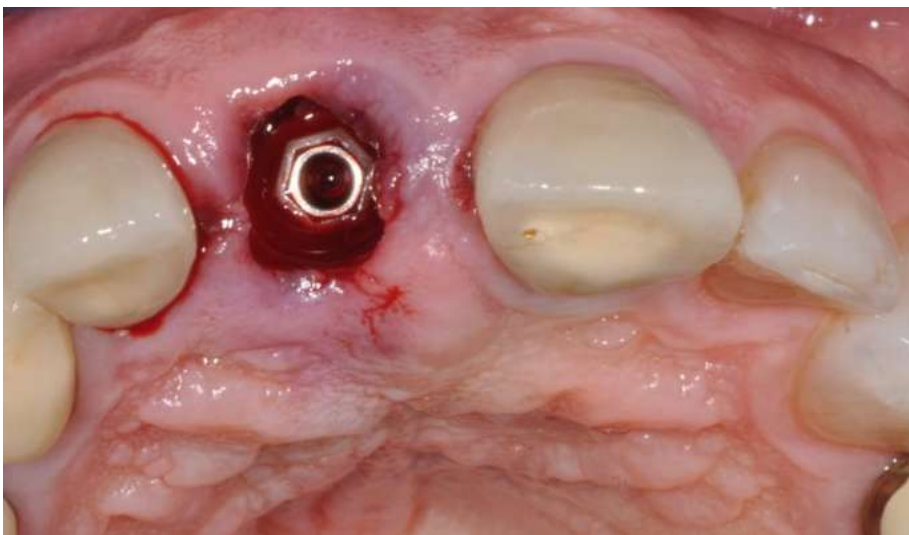
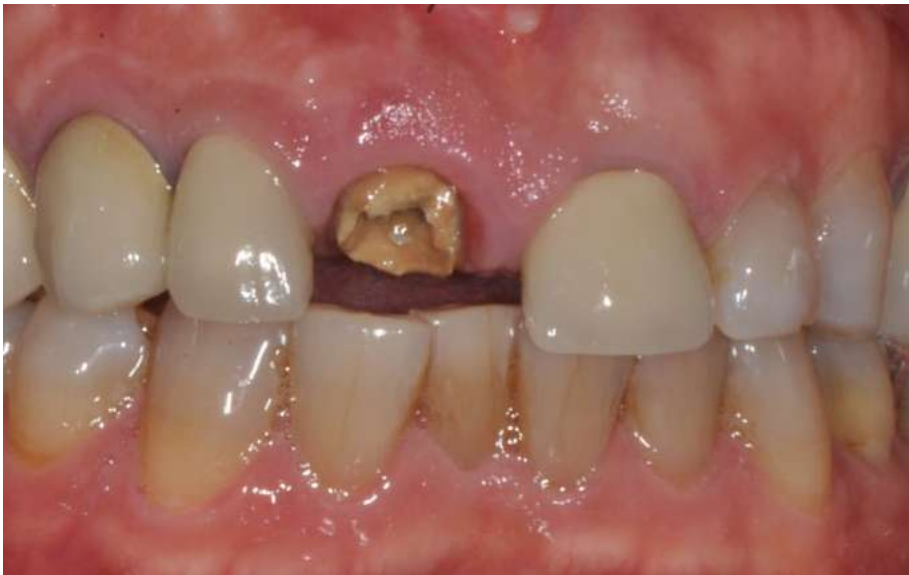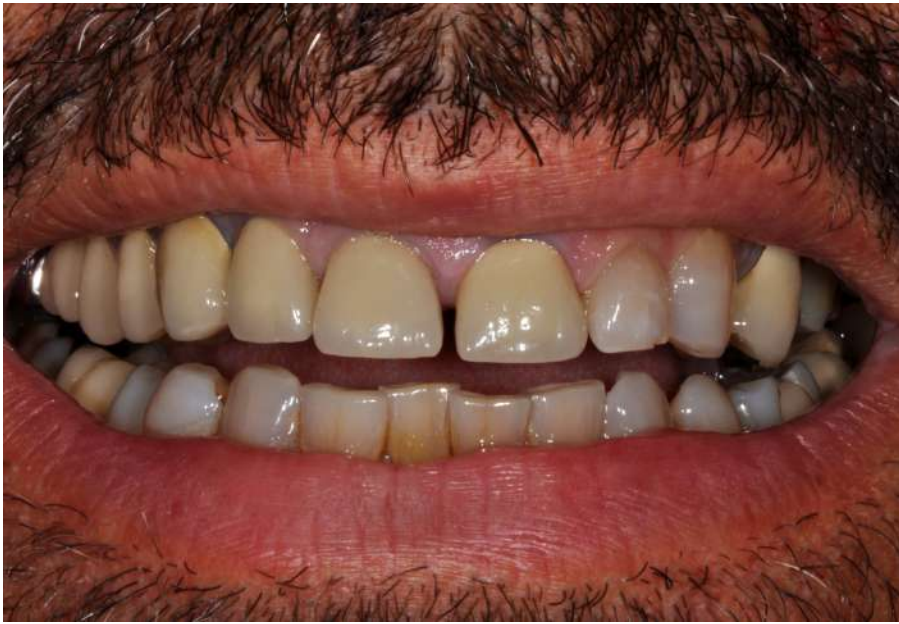SYSTEMIC ANAMNESIS: negative

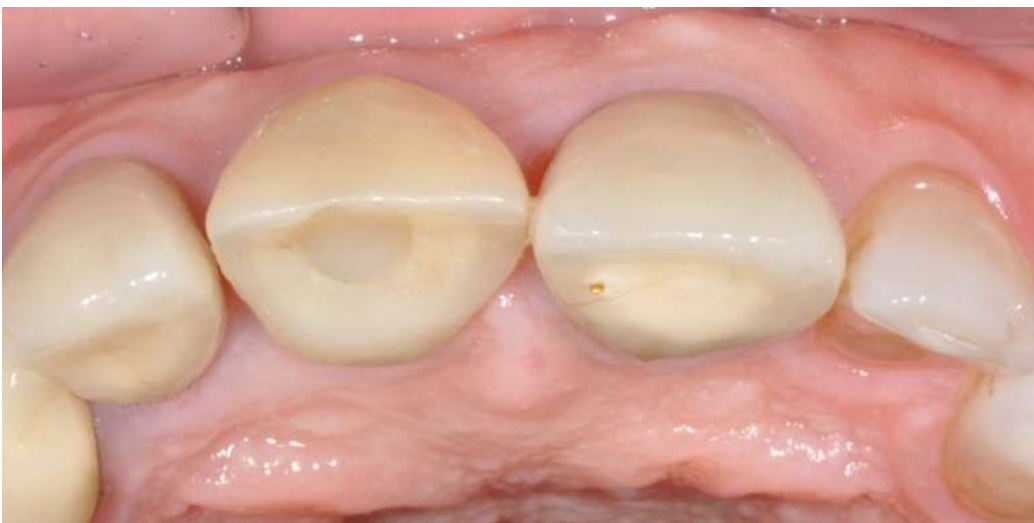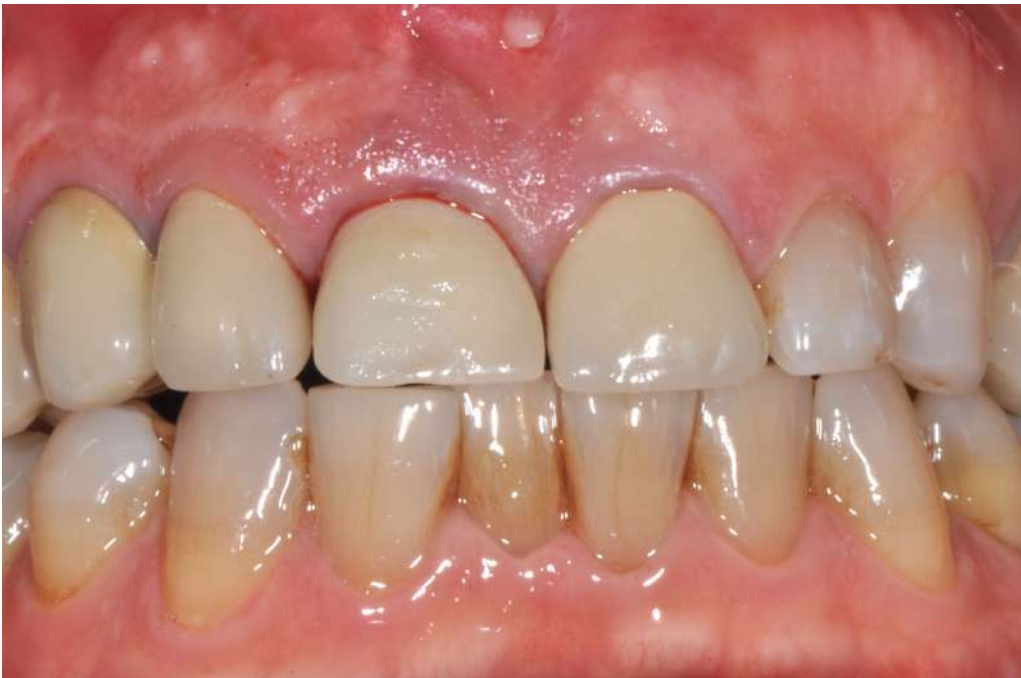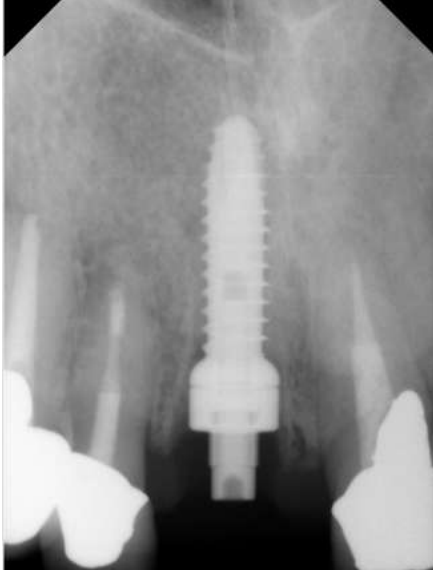SMOKING: 5 cigarette/day DRUGS TAKEN: nothing

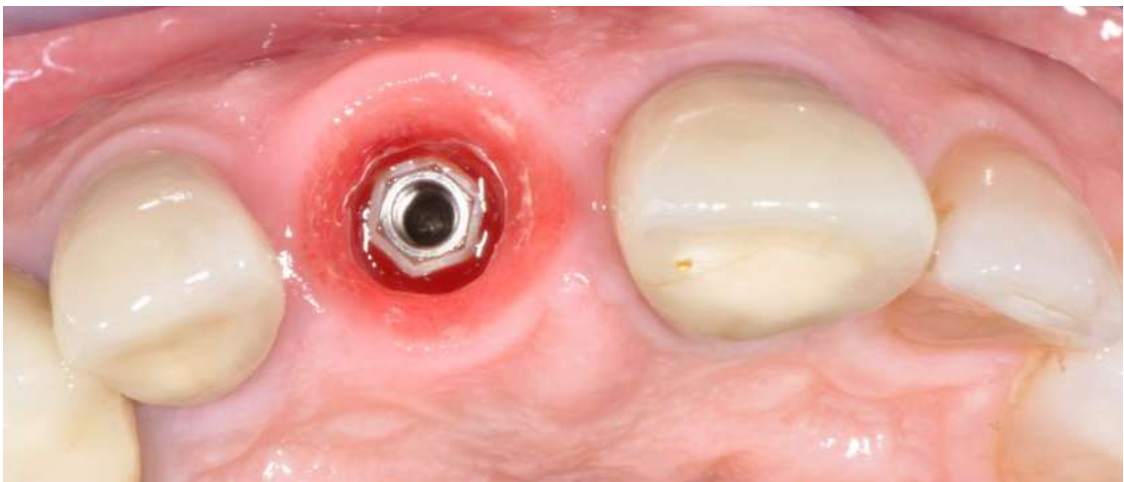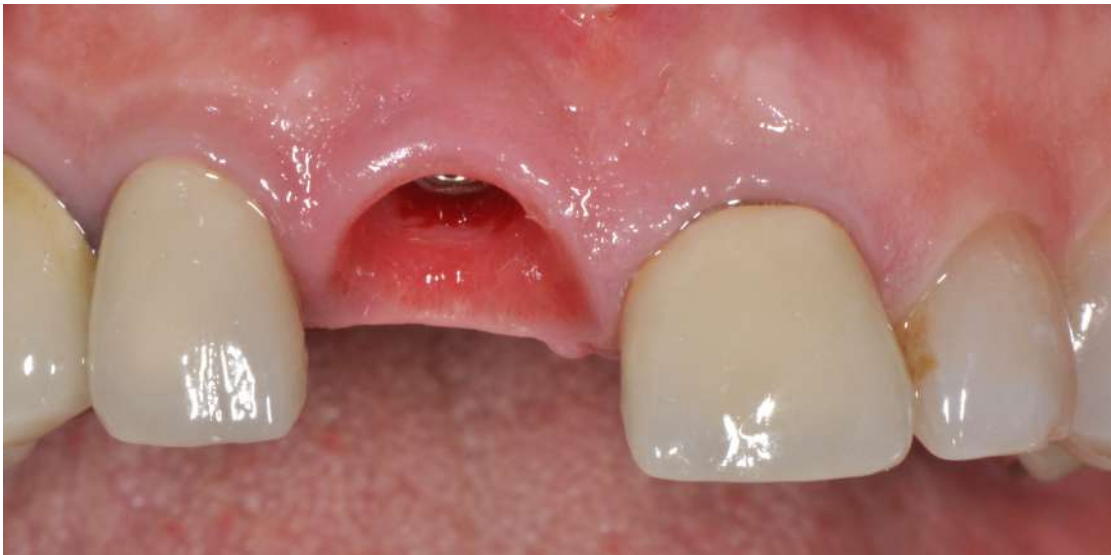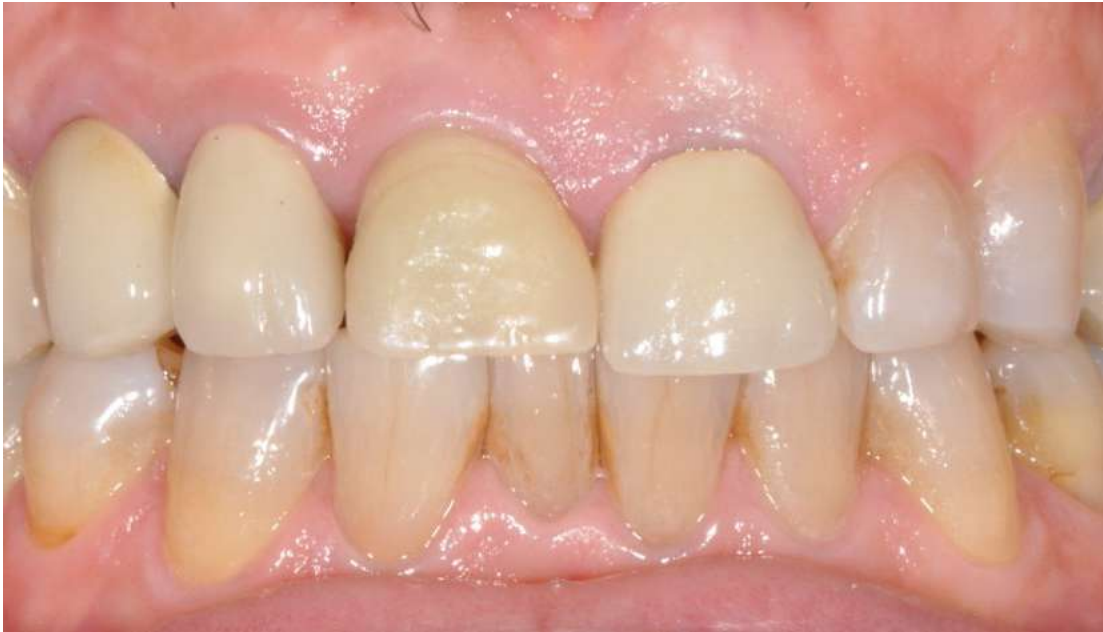DIAGNOSIS: fracture of tooth 11

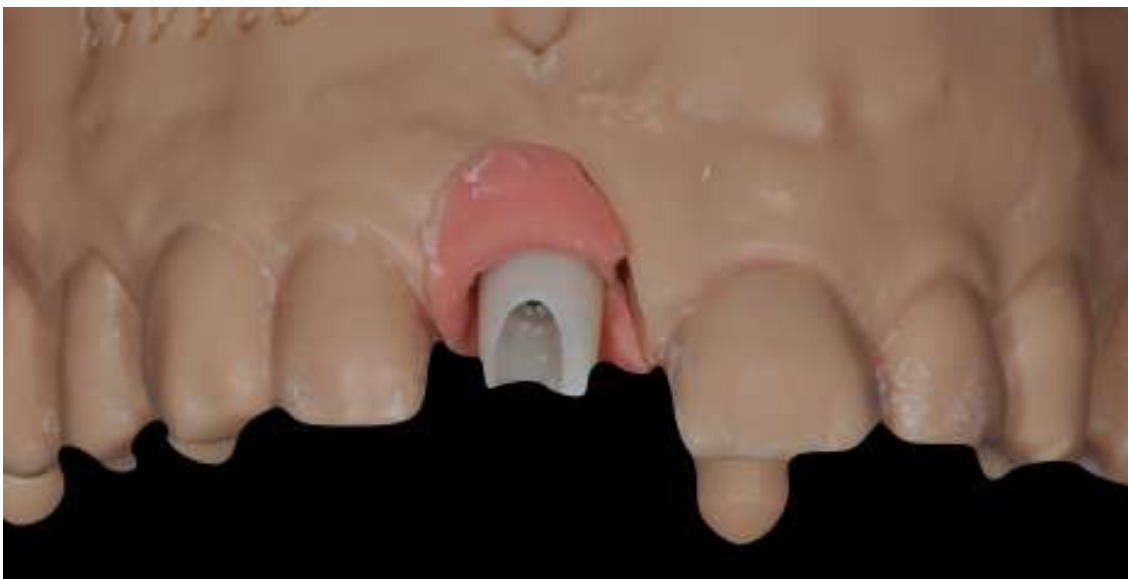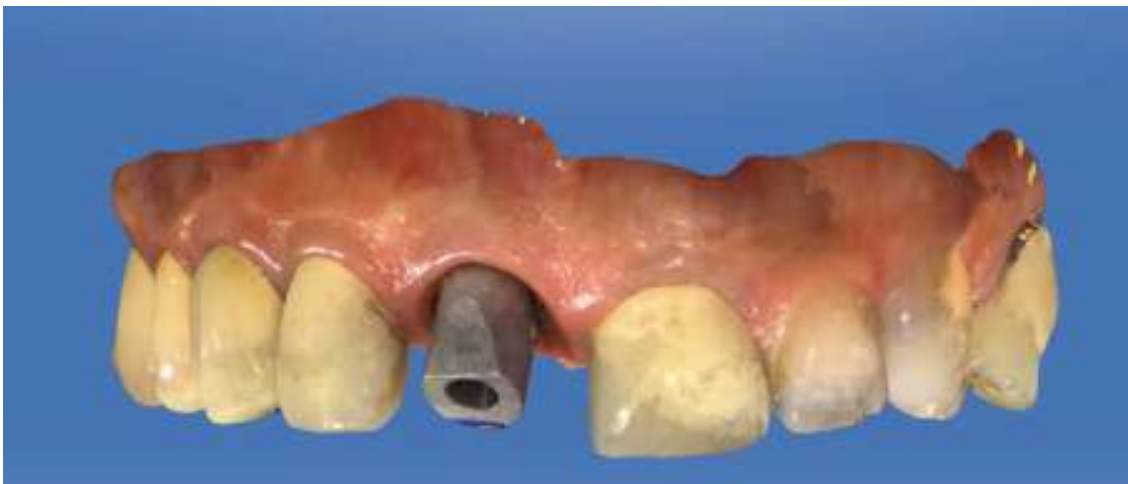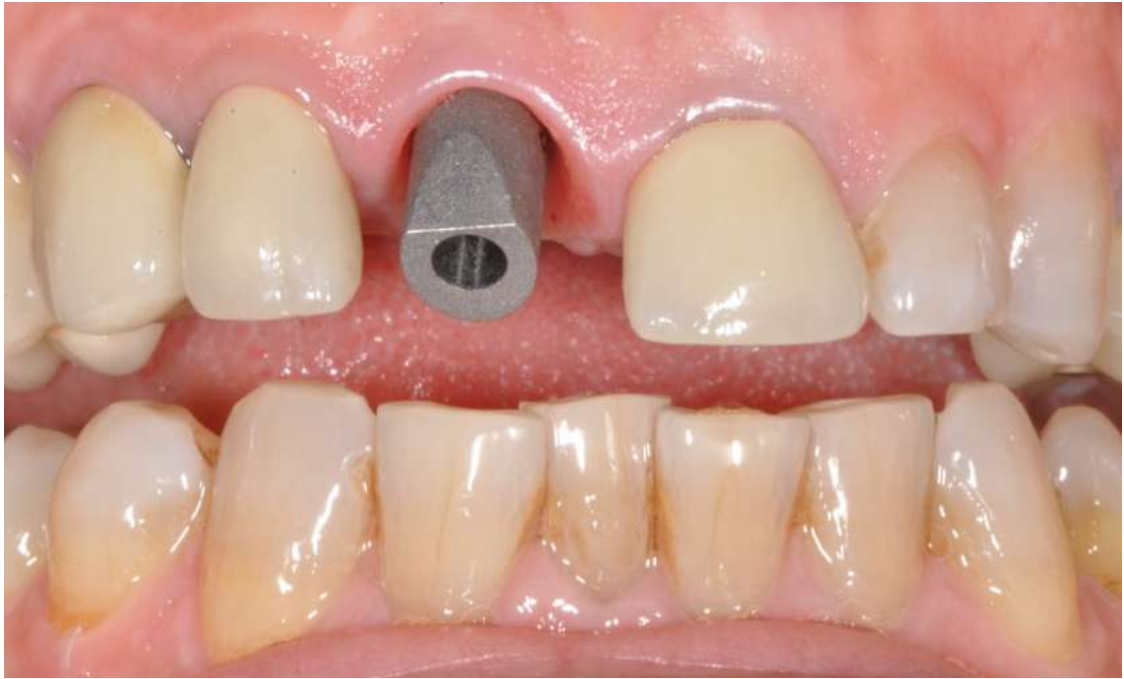THERAPY: extraction of 11 and post-extractive implant of 11 with immediate temporary screwed crown. After 4 months of healing, positioning of zirconium-ceramic crown cemented on zirconium abutment. Impression with intraoral digital scanner (Cerec - Sirona) and production of prototype model.

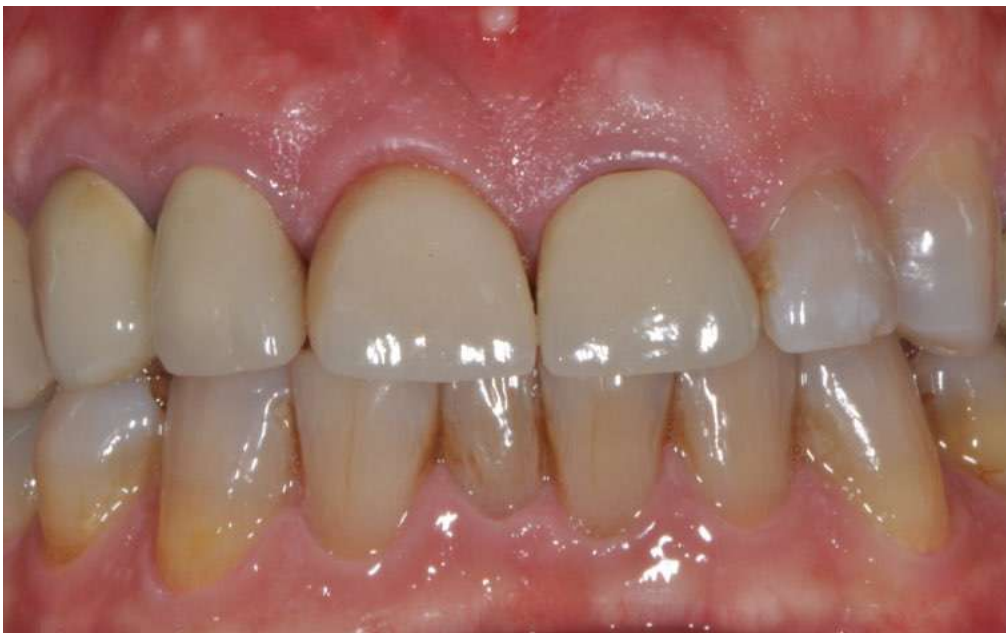
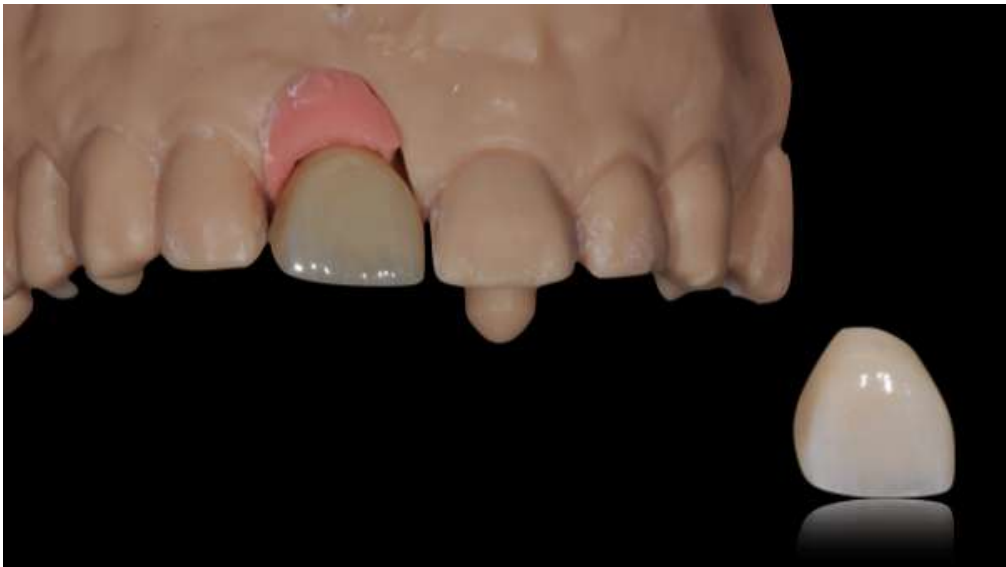
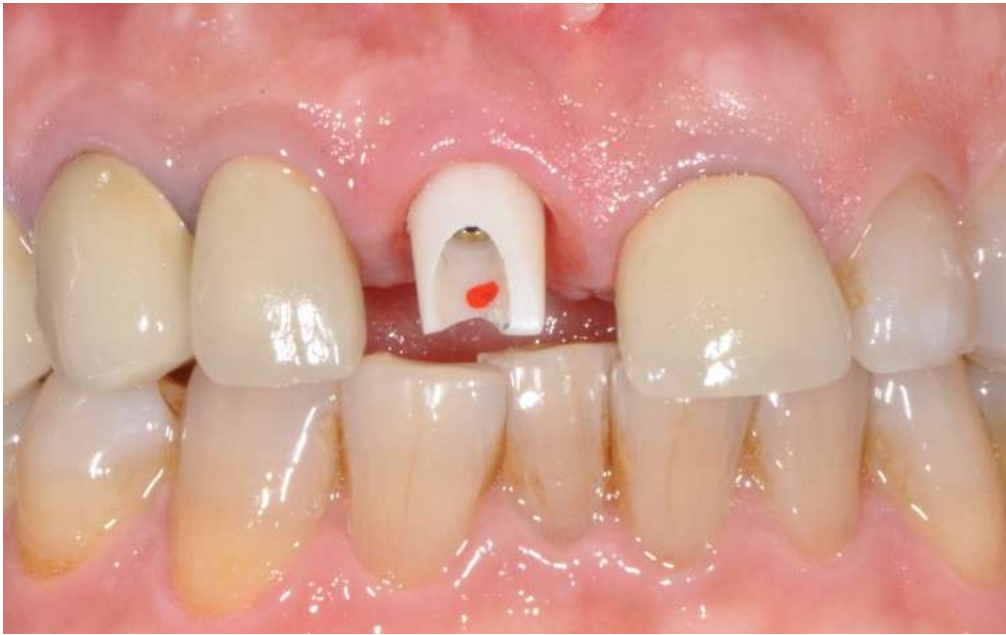


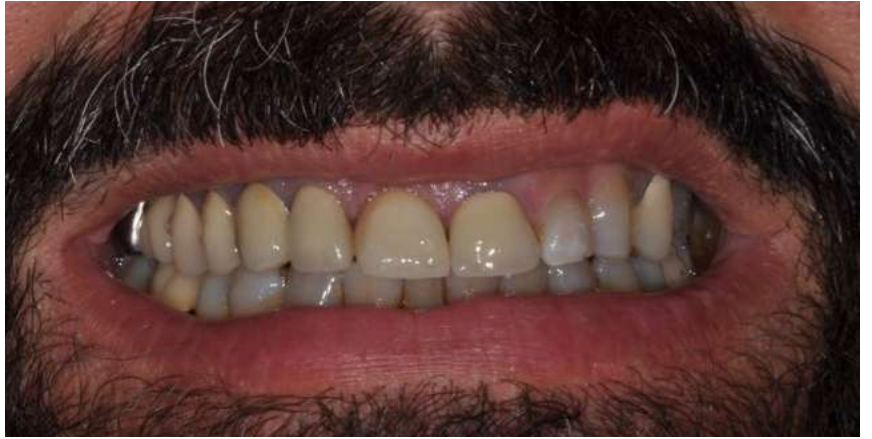
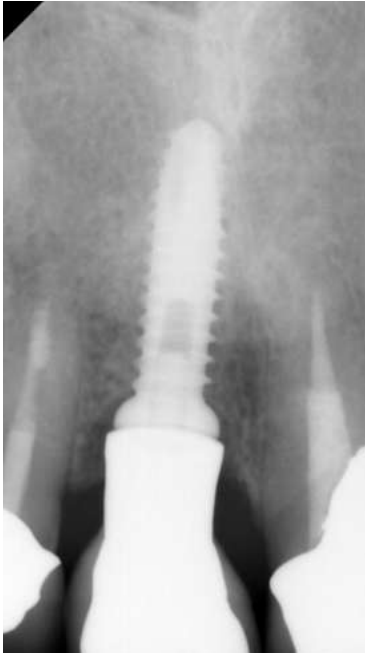







Follow-up at 2 years

