

CASE 2

SEX: Male AGE: 52 years old NAME: M.R.

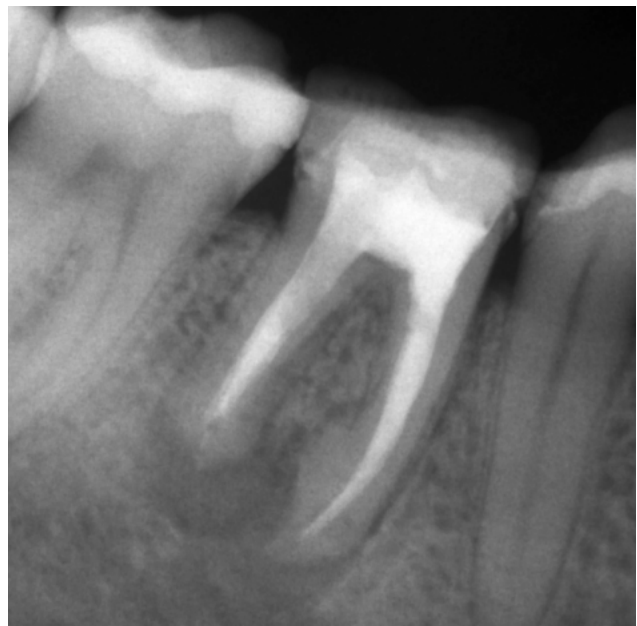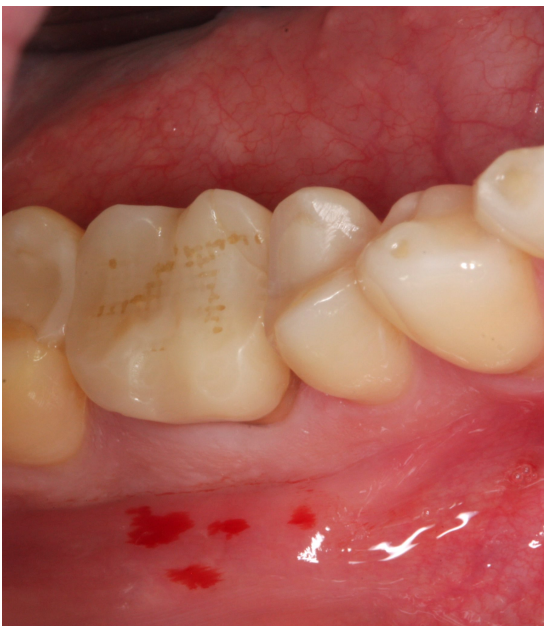SYSTEMIC ANAMNESIS: negative

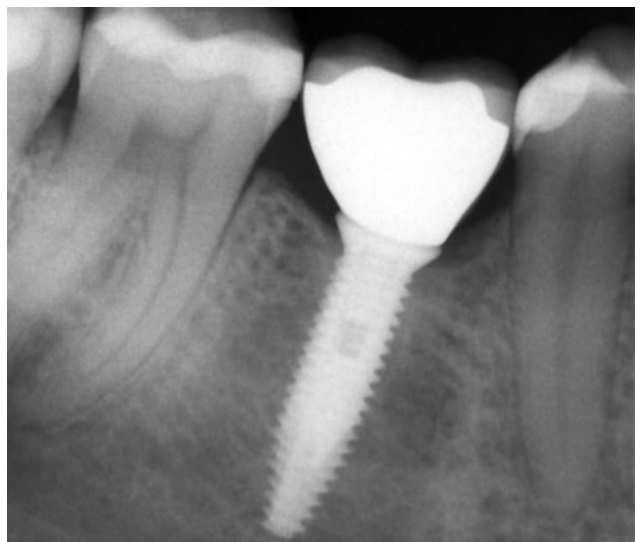
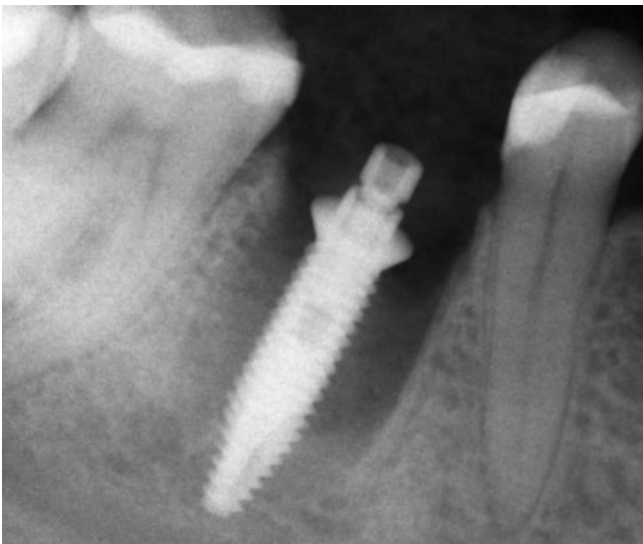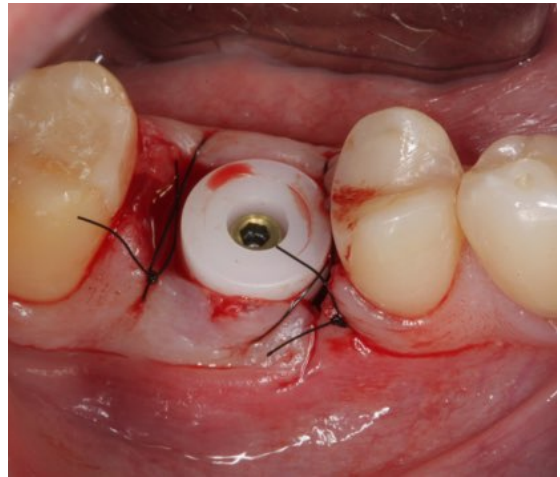
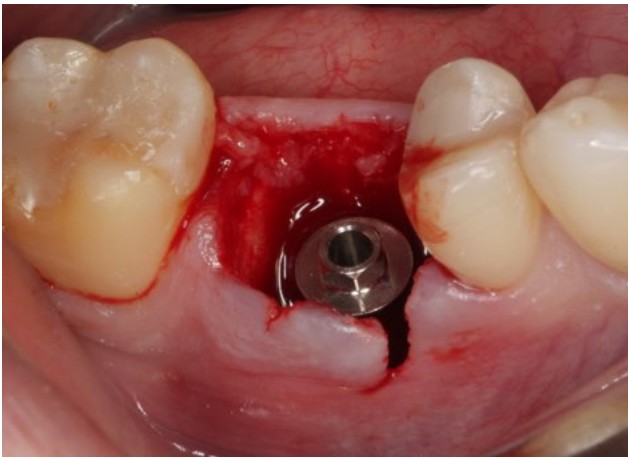
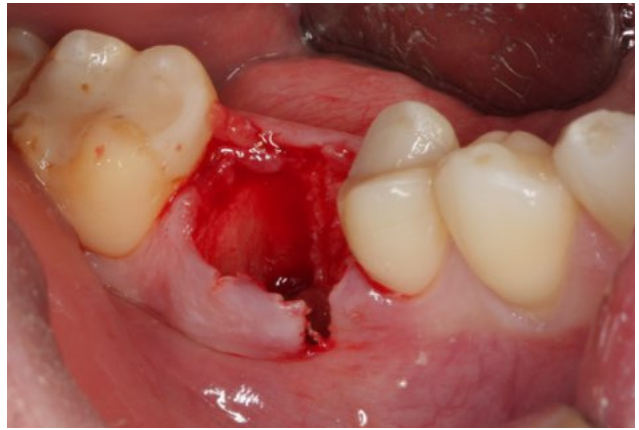
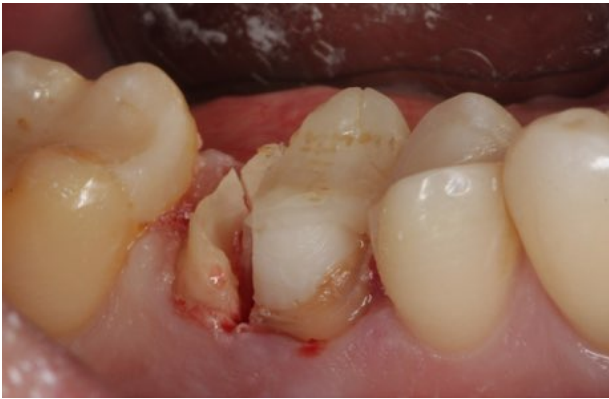SMOKING: negative

DRUGS TAKEN: nothing

DIAGNOSIS: endodontic disease of 46

THERAPY: extraction of 46 and immediate post-extraction implant. After 4 months of healing with healing caps, positioning of zirconium-ceramic screwed definitive crown.





Follow-up at 2 years