

CASE 1

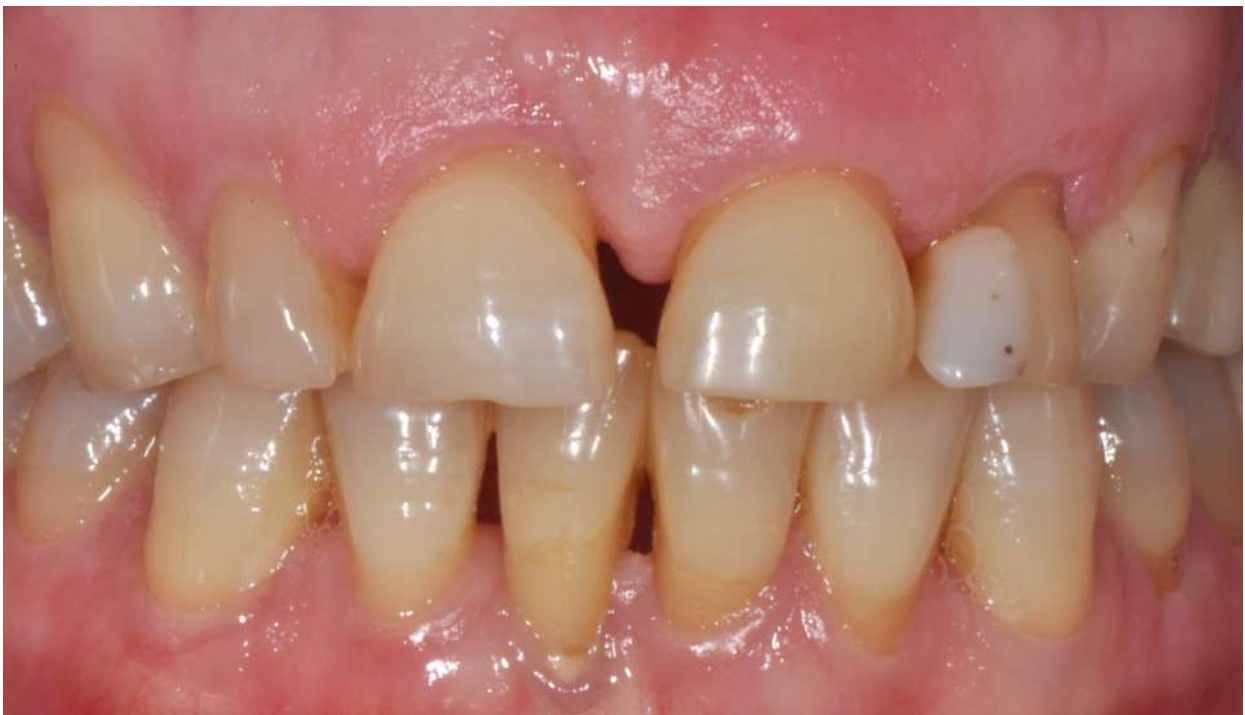SEX: Female AGE: 60 years old NAME: G.M.

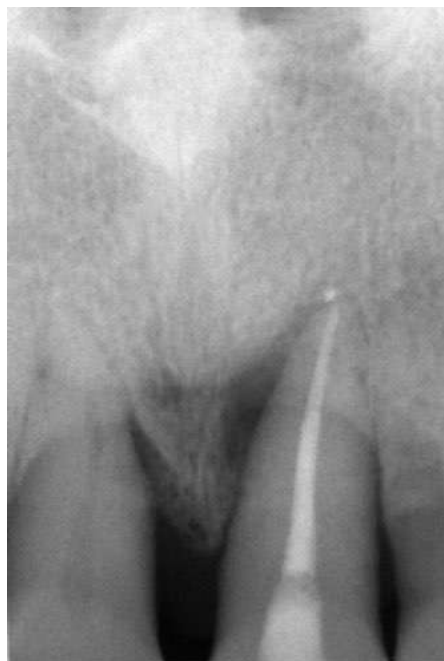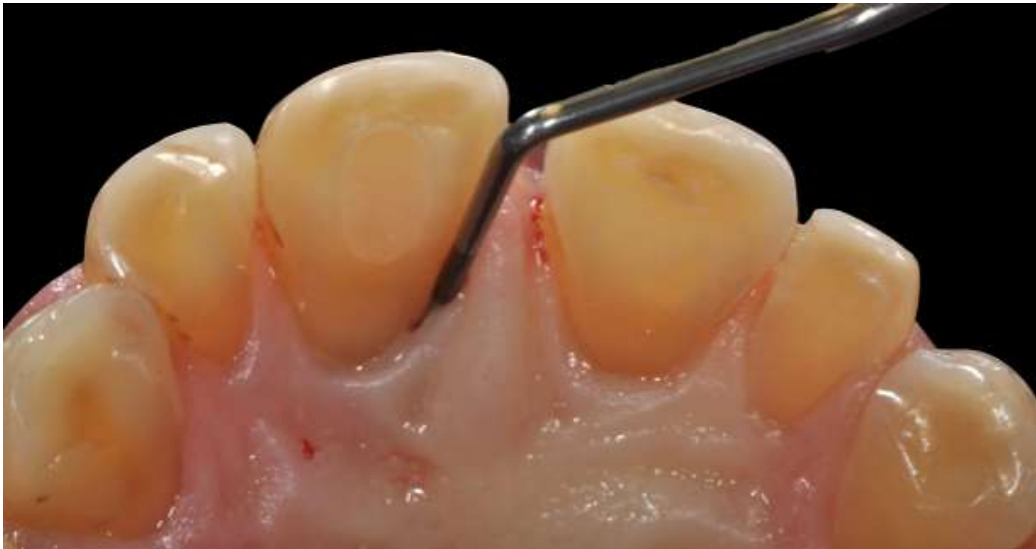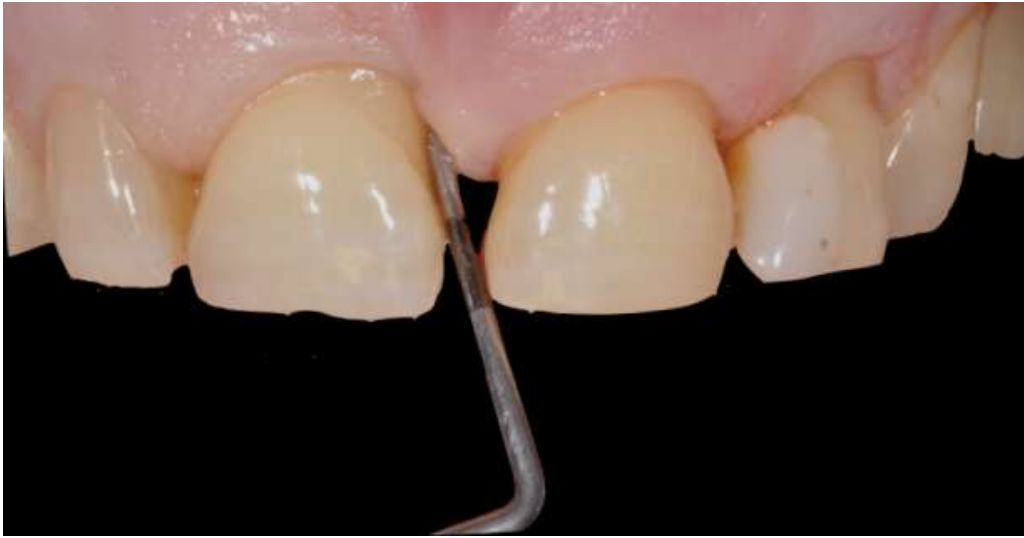SYSTEMIC ANAMNESIS: breast cancer 12 years before

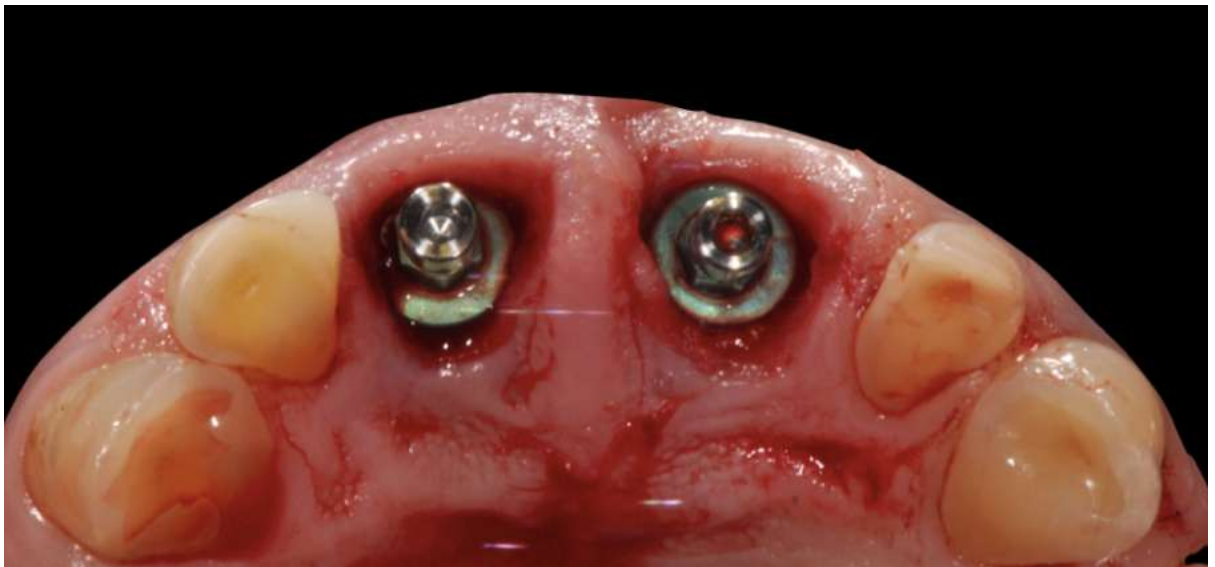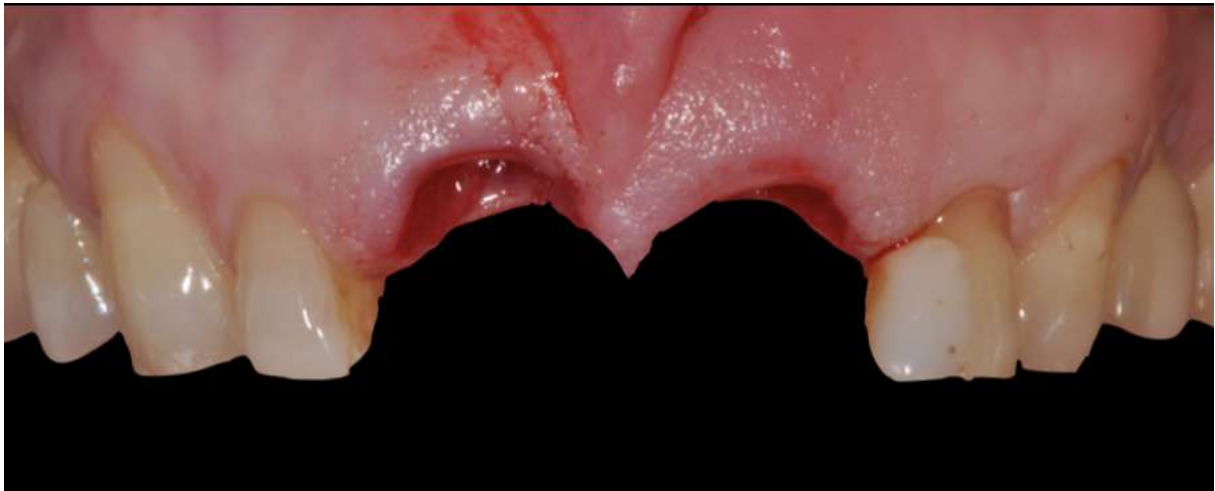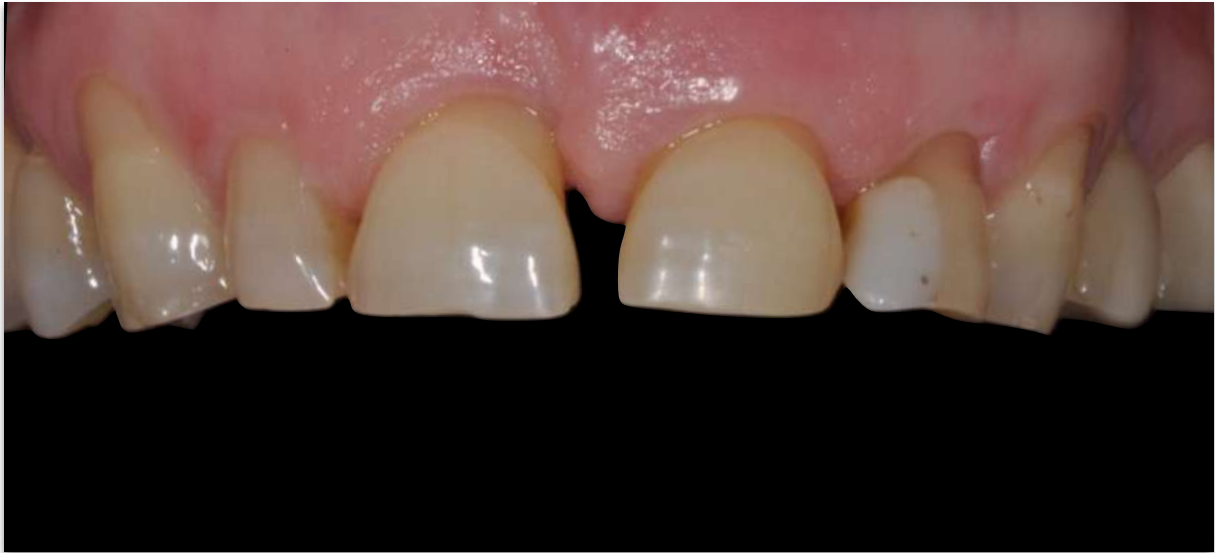SMOKING: negative DRUGS TAKEN: nothing

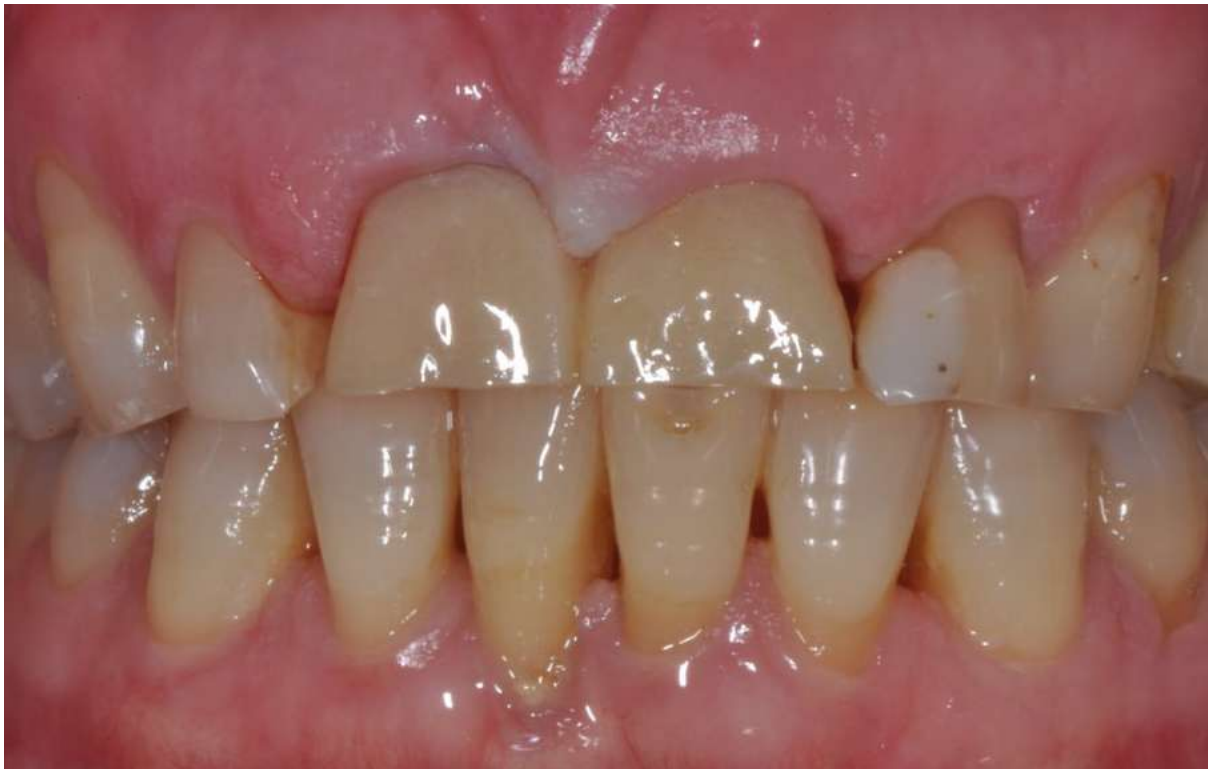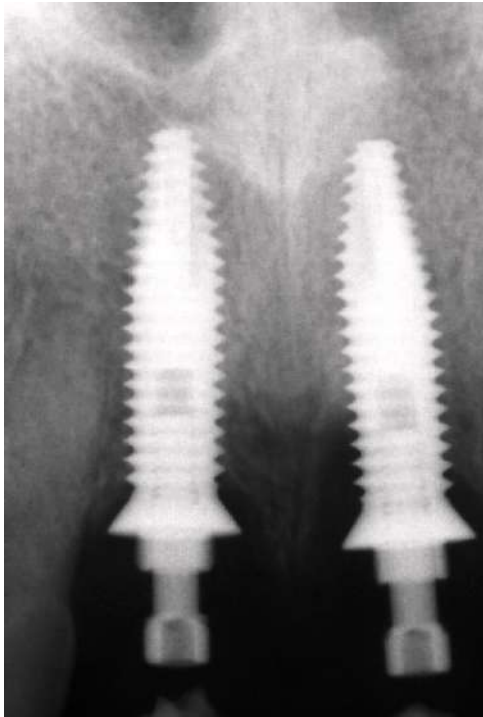
DIAGNOSIS: periodontal disease of 11 and 21 that does not respond to periodontal therapies. Poor prognosis of 11-21.

THERAPY: extraction of 11 and 21 and replacement with two immediate post-extraction implants with immediate temporary screwed crowns. After 4 months of healing, zirconium-ceramic definitive crowns was cemented on zirconium abutments.

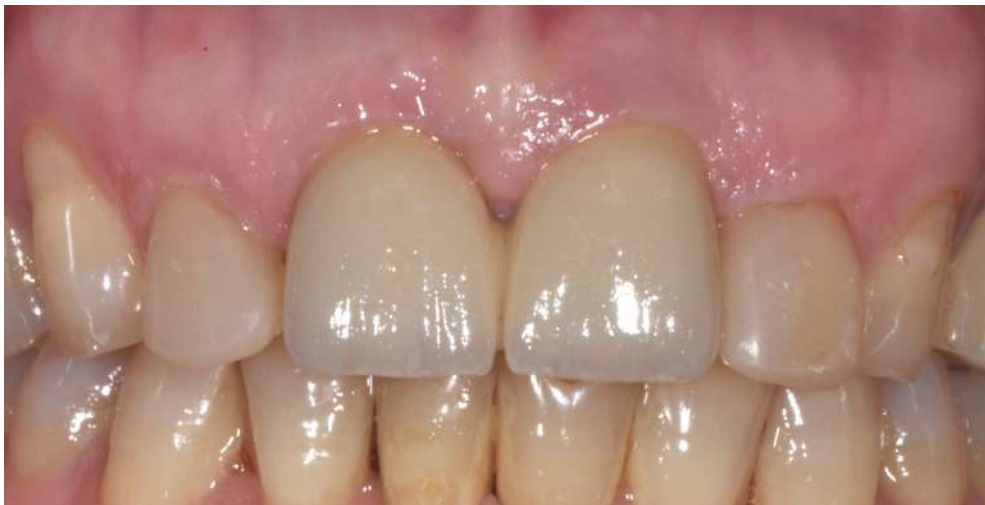
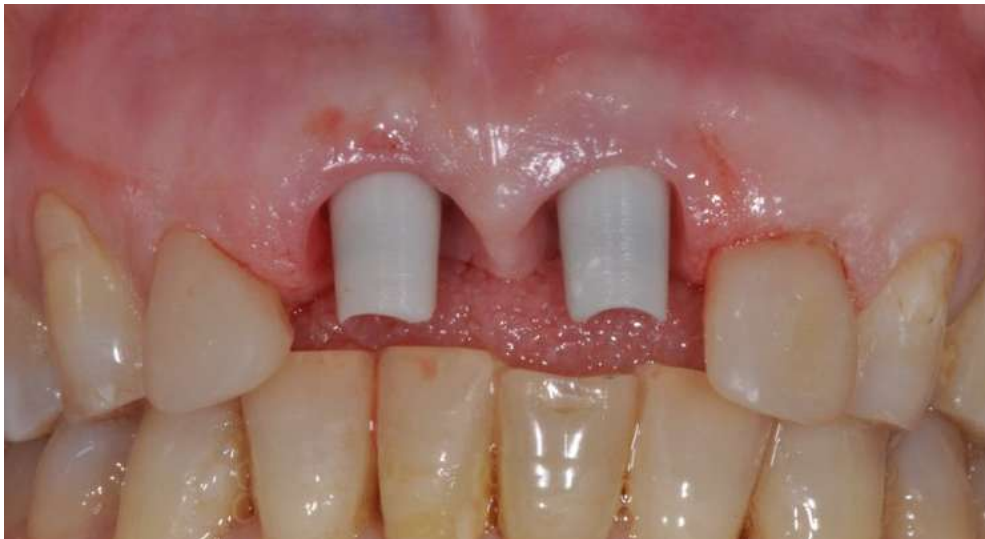
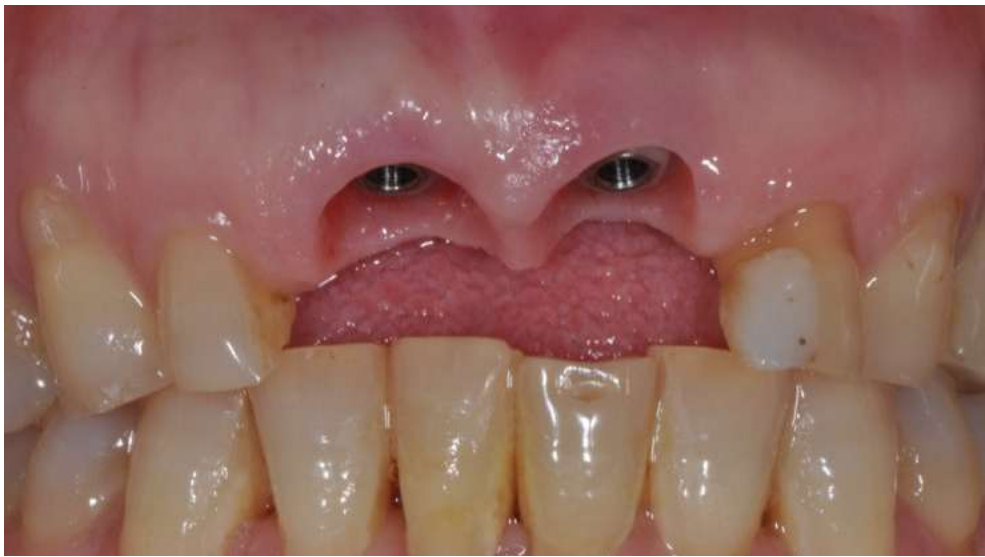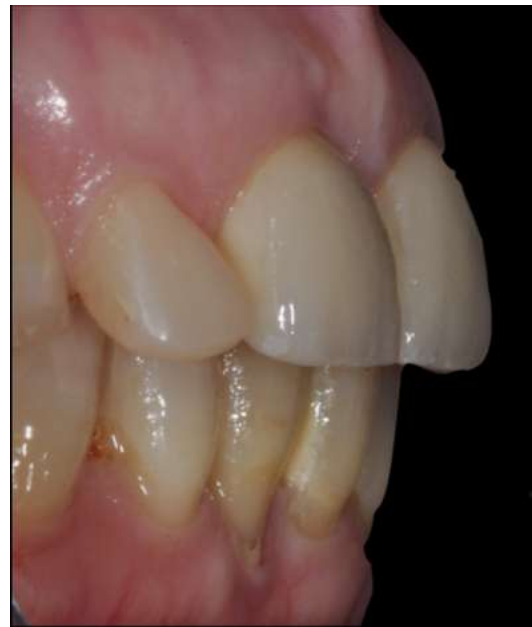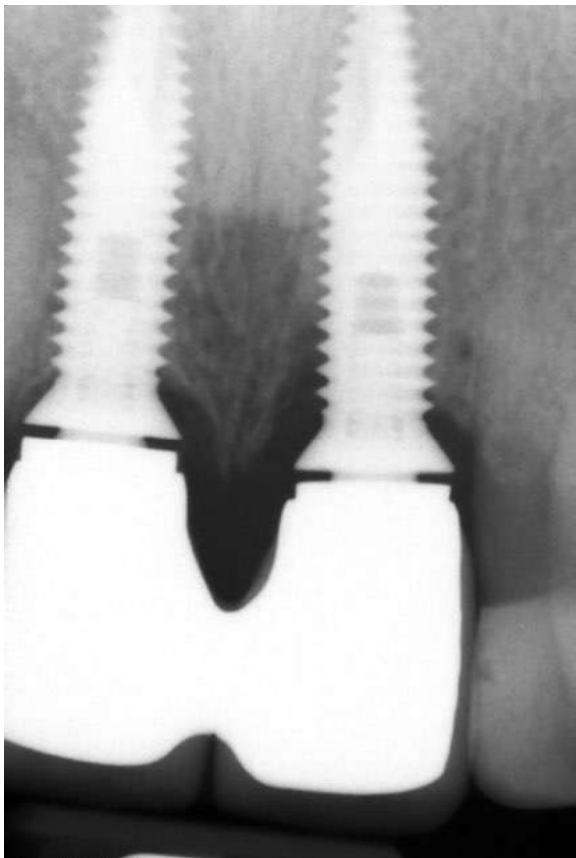




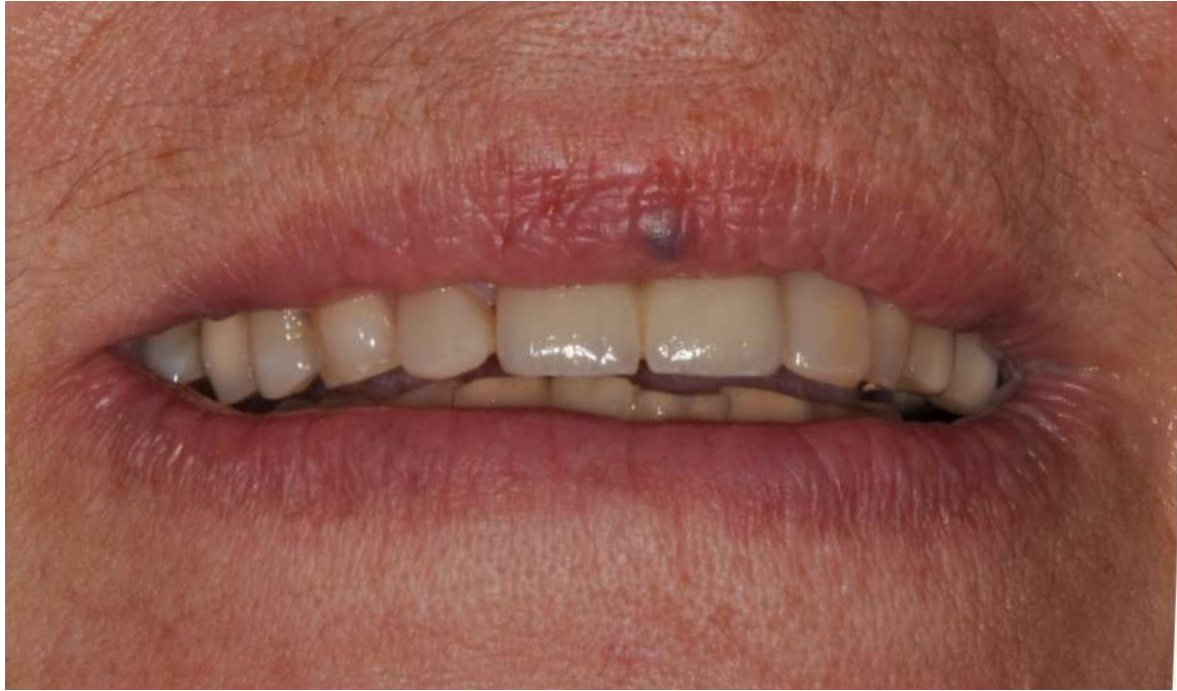

Immediately temporary screwed crowns





Follow-up at 8 years

