

## CASE 4

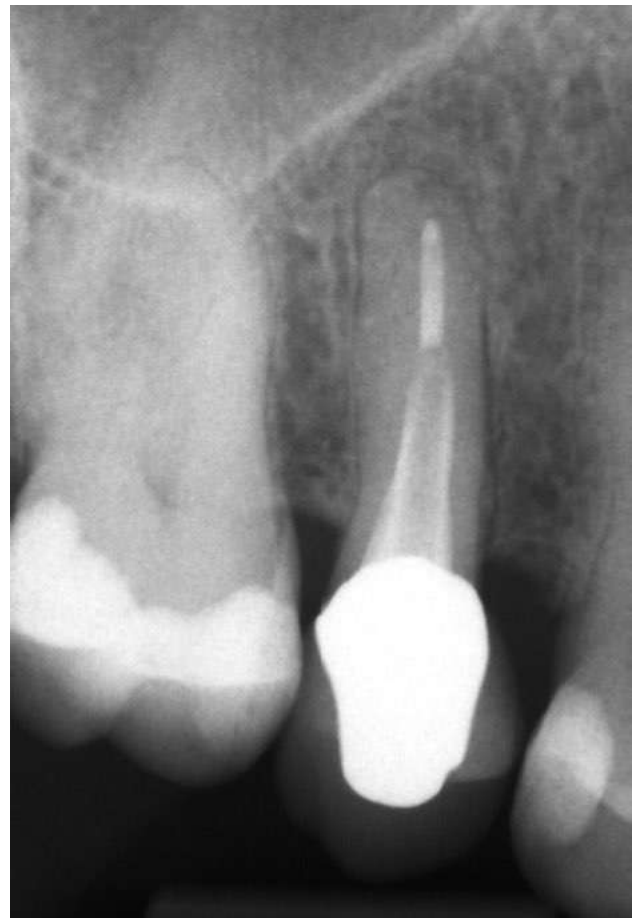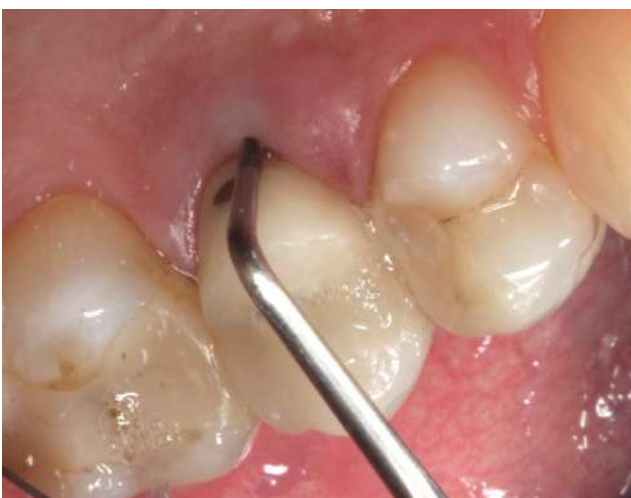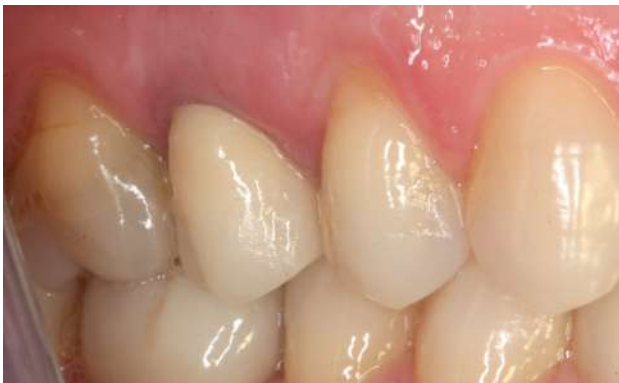SEX: Female AGE: 48 years old NAME: D.P.

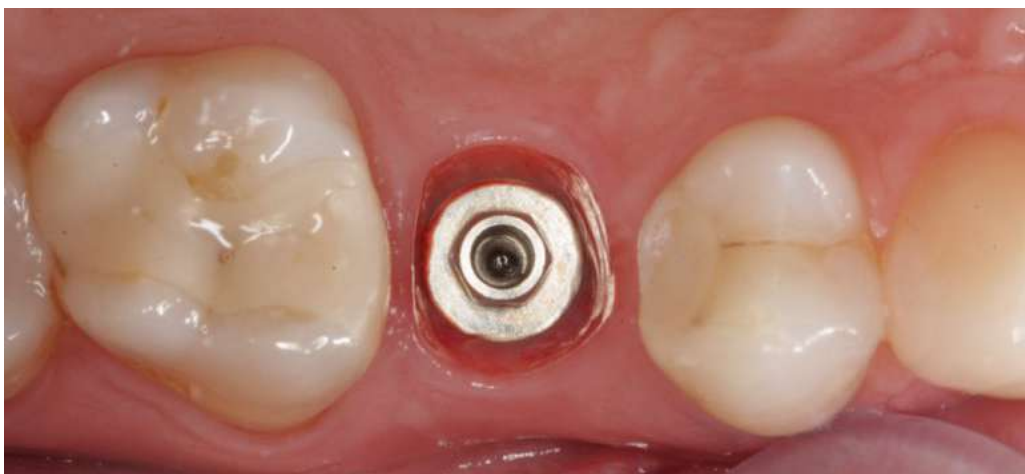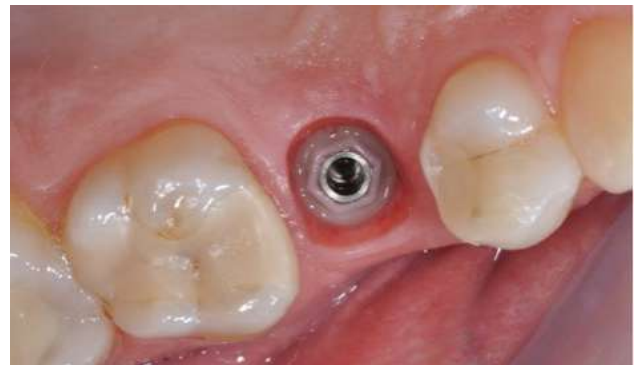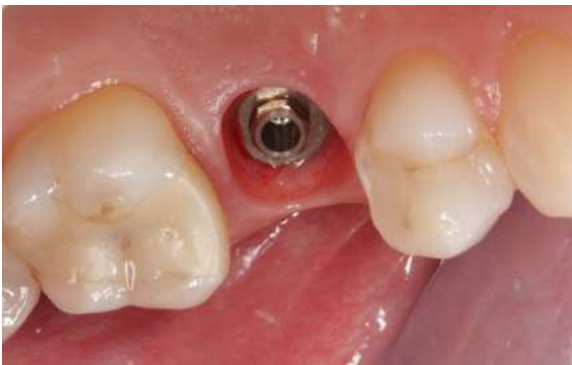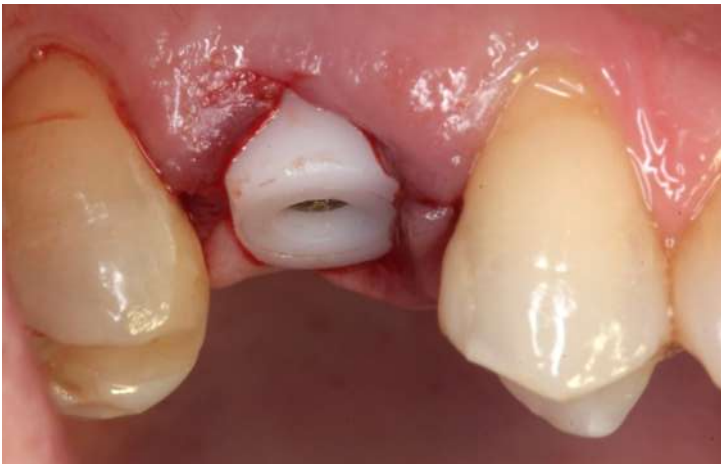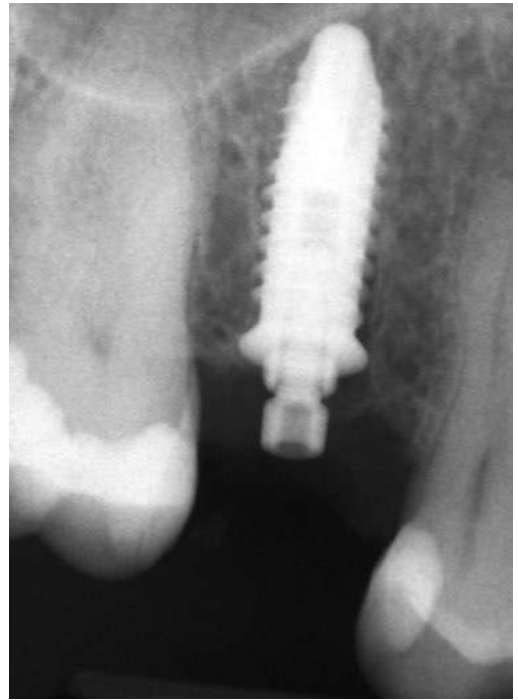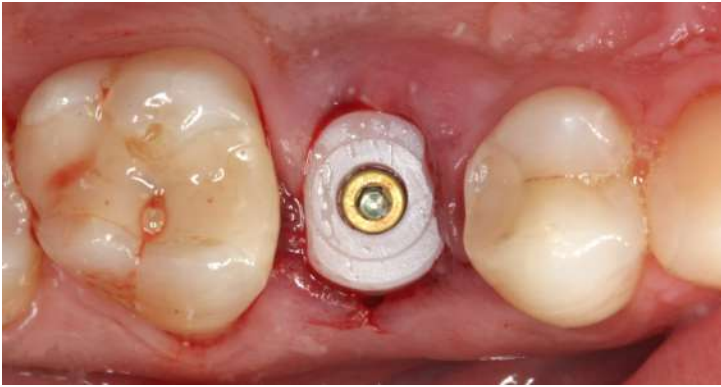SYSTEMIC ANAMNESIS: negative

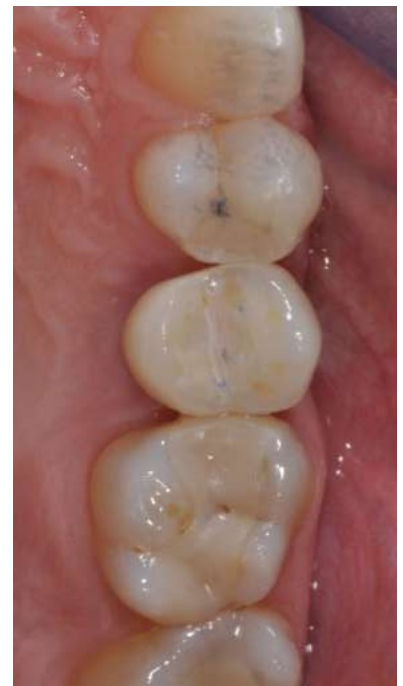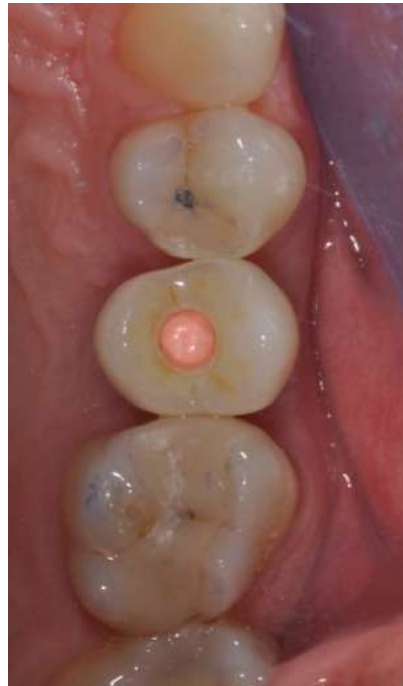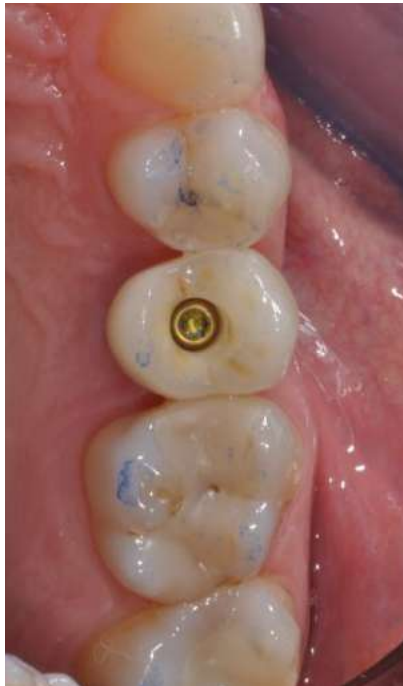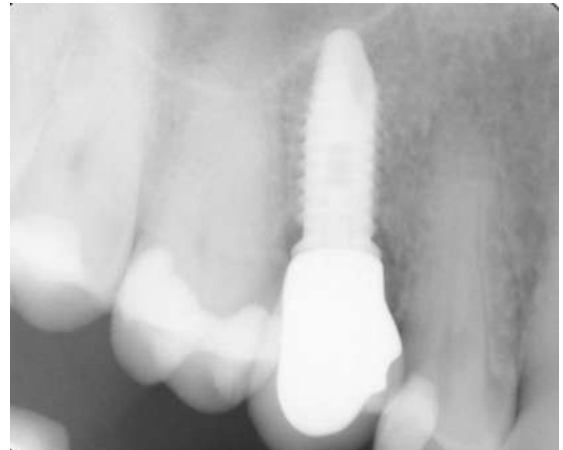
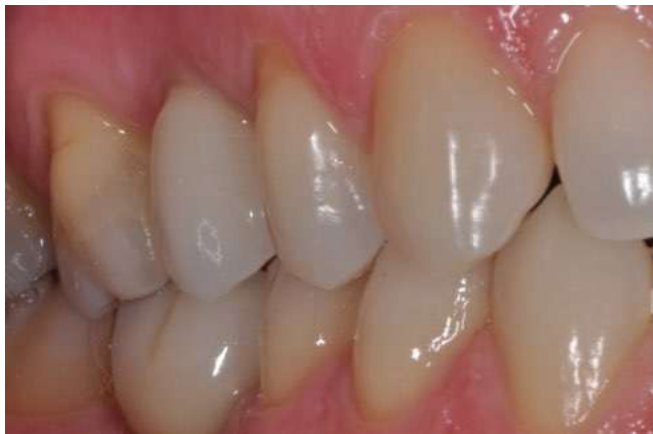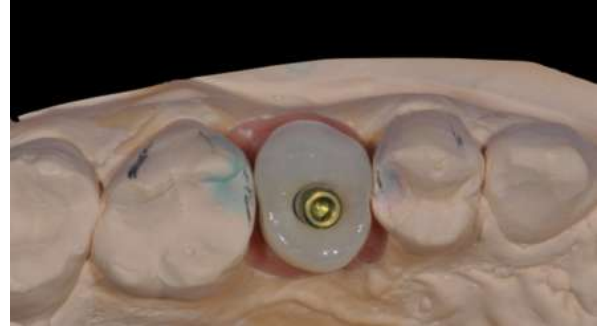
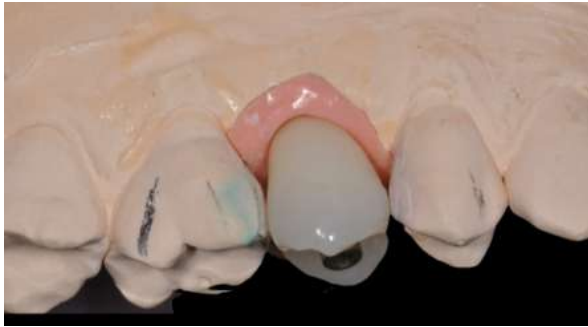SMOKING: negative DRUGS TAKEN: nothing

DIAGNOSIS: tooth fracture of 15

THERAPY: extraction of 15 and immediate post-extraction implant. After 4 months of healing with a caps, zirconium-ceramic screwed crowns was placed.









Follow-up at 10 years

