

## CASE 10

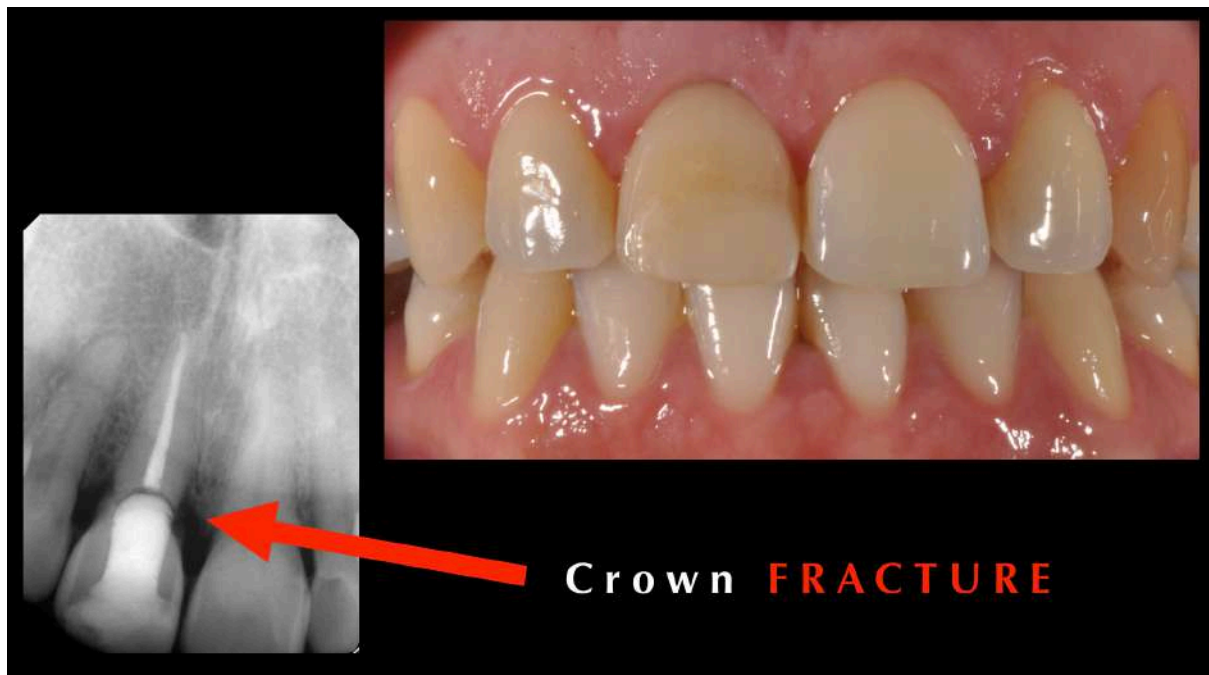
SEX: Female AGE: 42 years old NAME G.L.

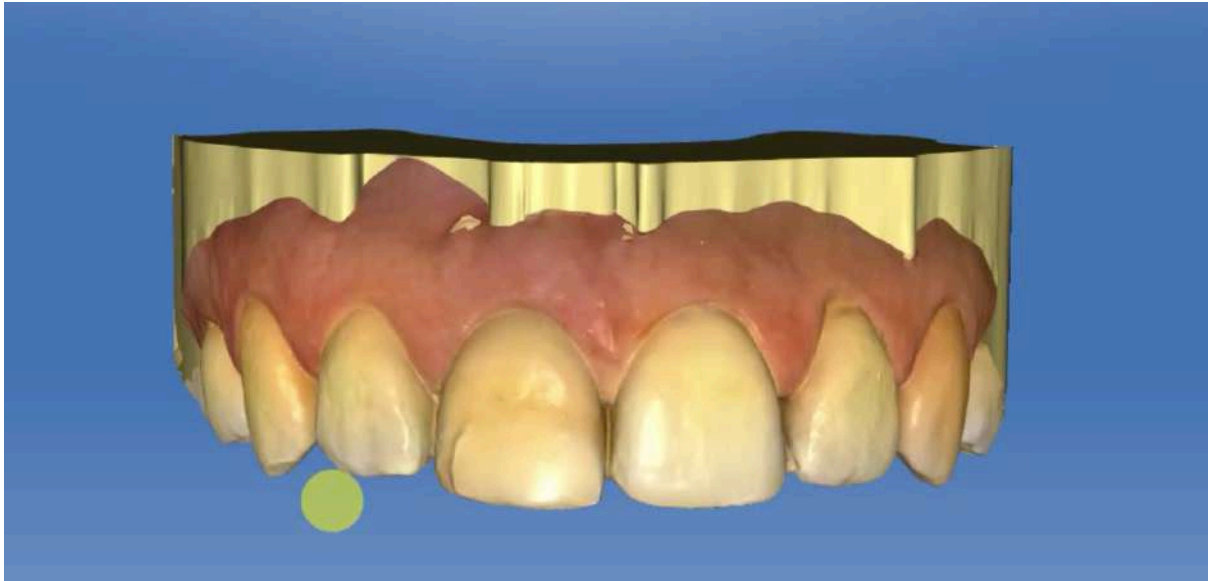SYSTEMIC ANAMNESIS: negative

SMOKING: nothing DRUGS TAKEN: nothing

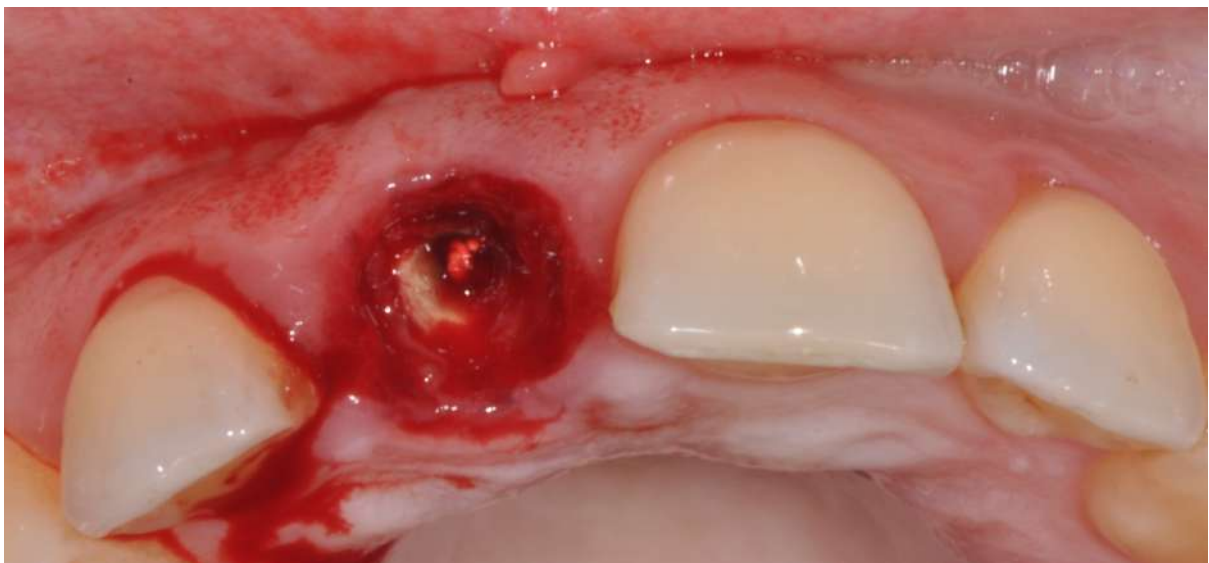
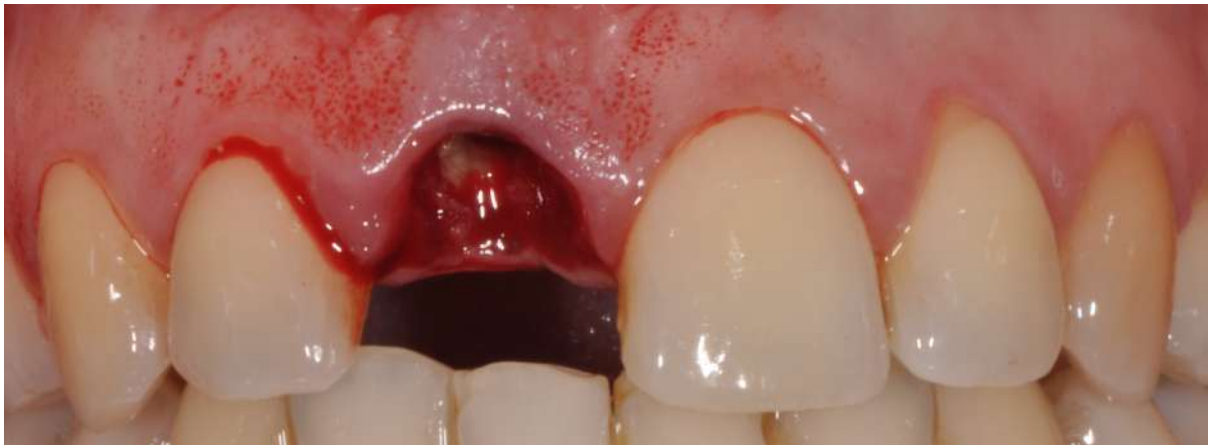DIAGNOSIS: tooth fracture of 11

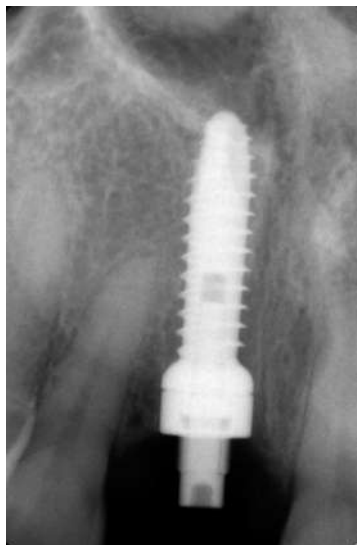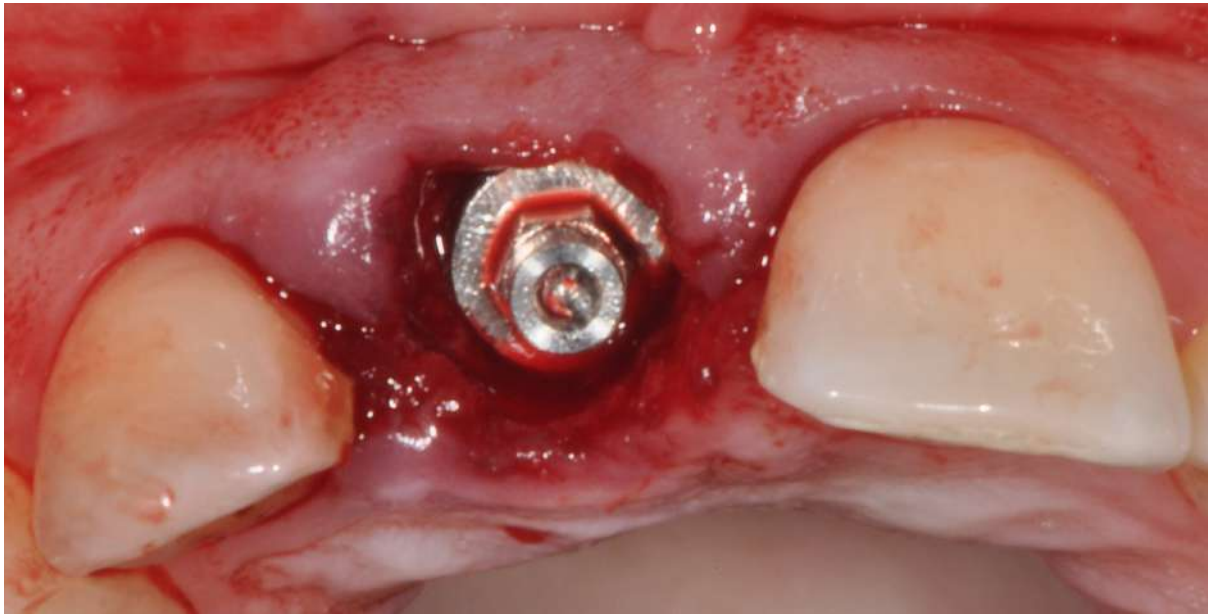
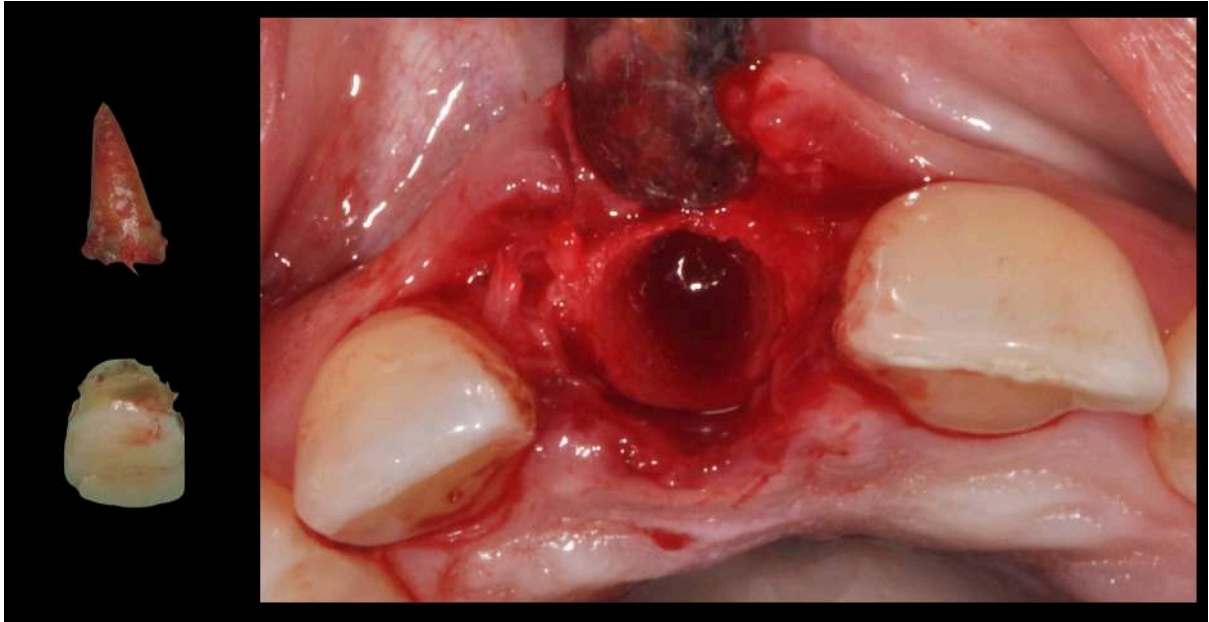
THERAPY: extraction and immediate post-extractive implant of 11 with immediate temporary screwed crown. After 4 months of healing, a zirconium-ceramic screwed crown was placed. Impression with intraoral digital scanner (Cerec - Sirona).

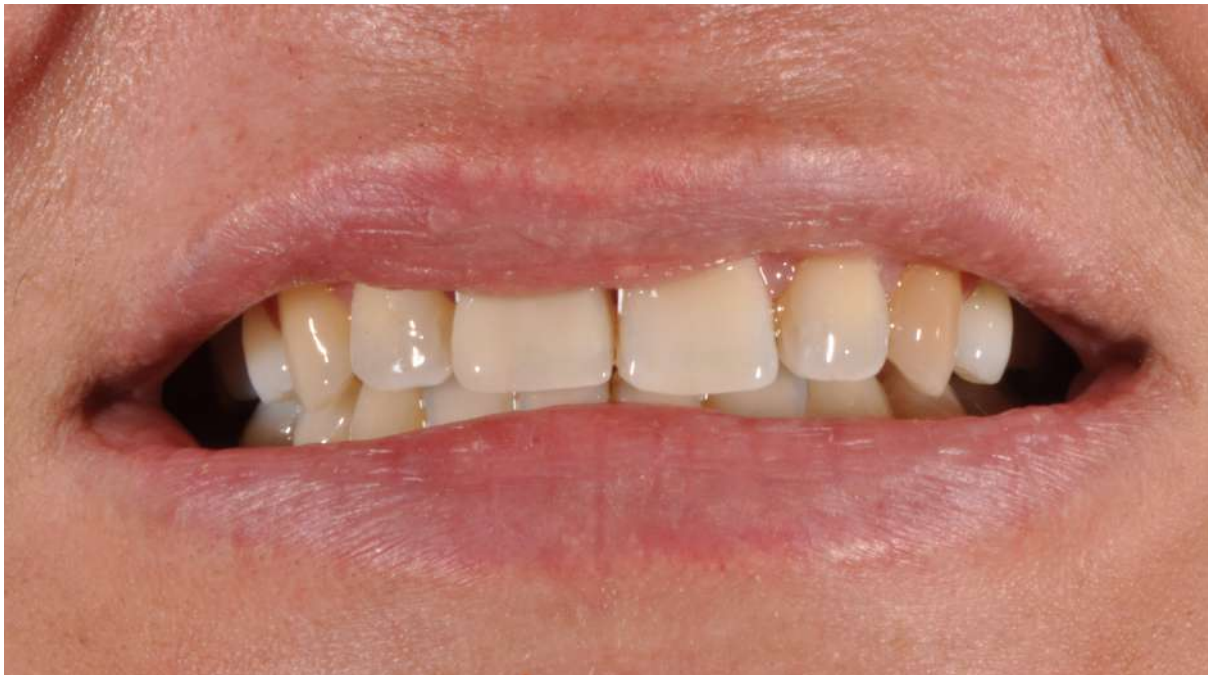
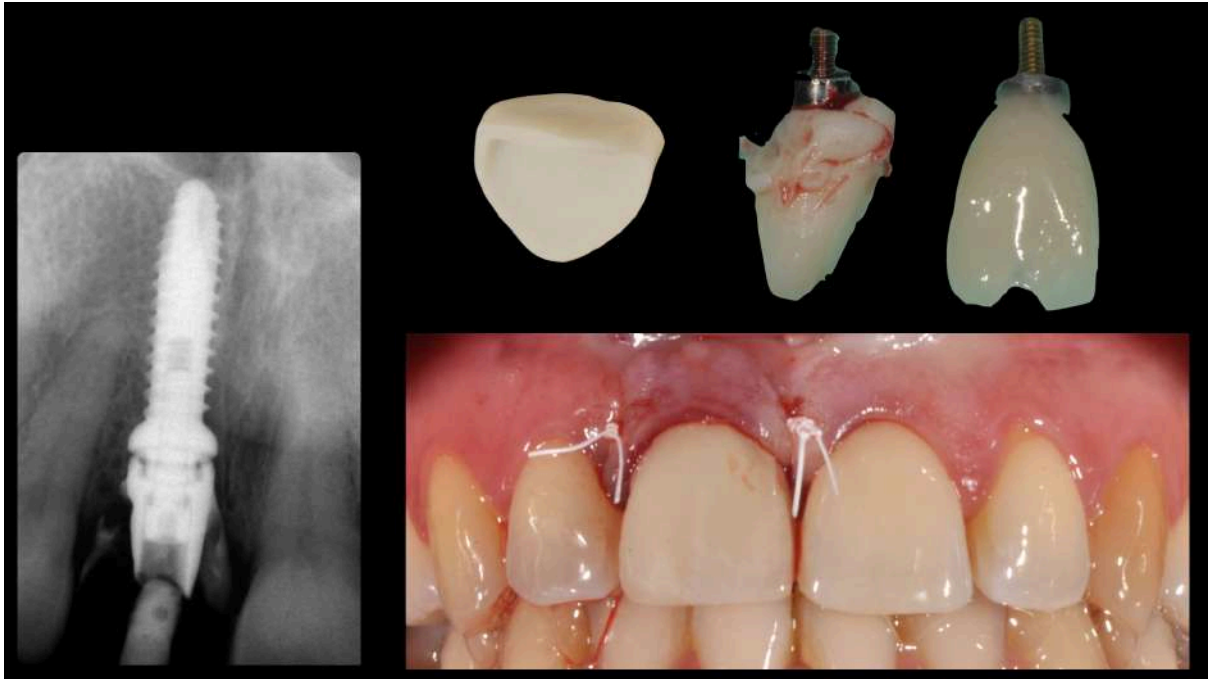


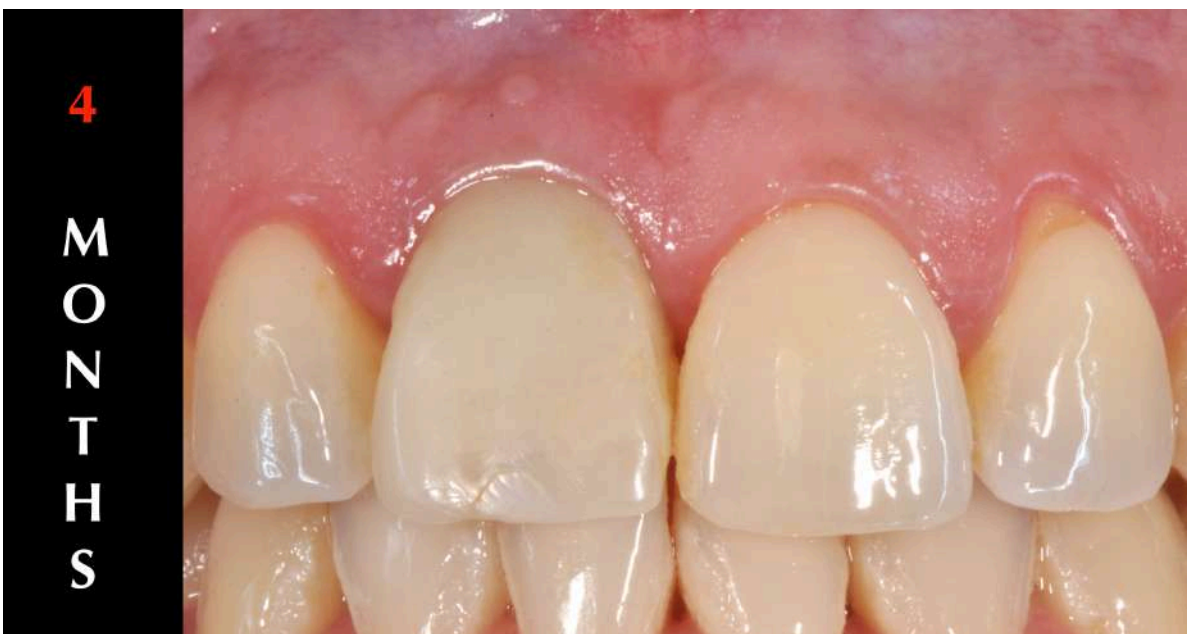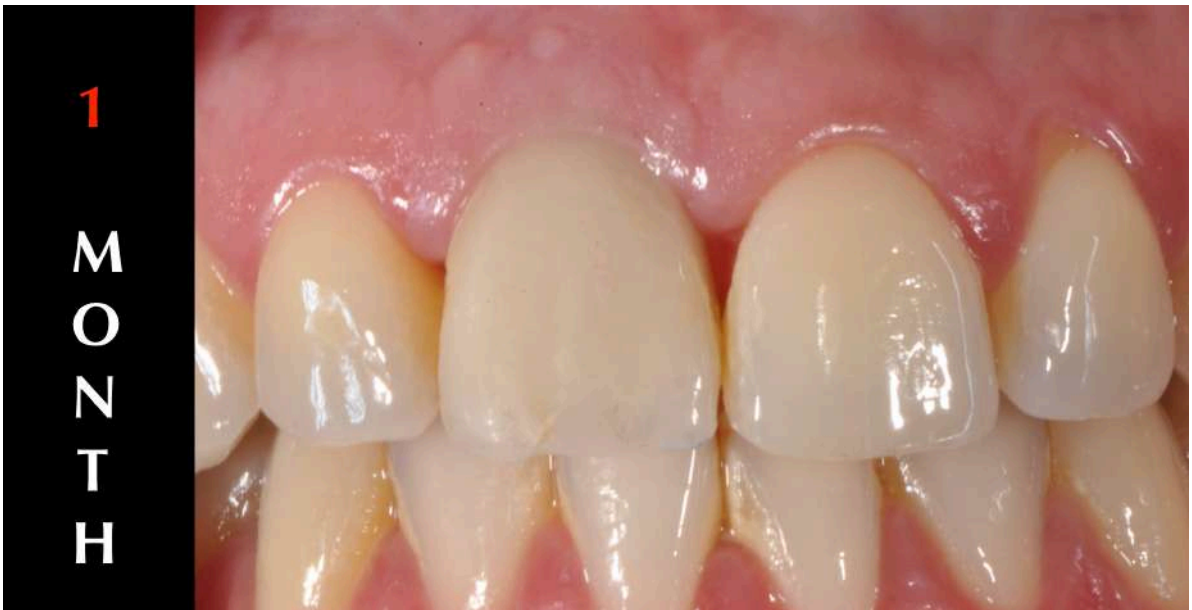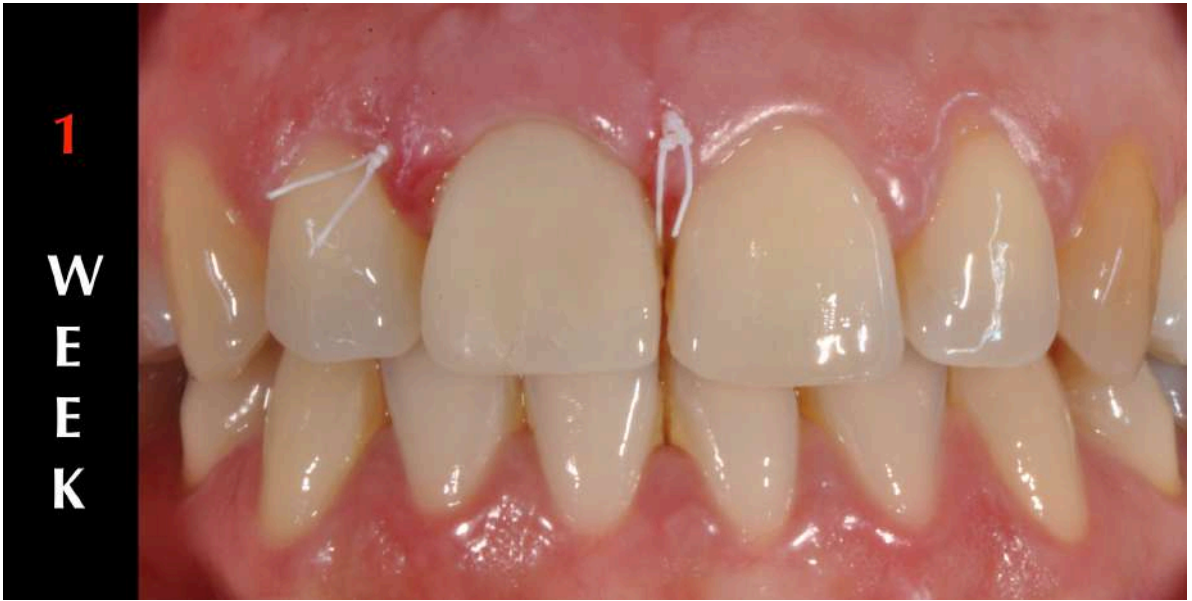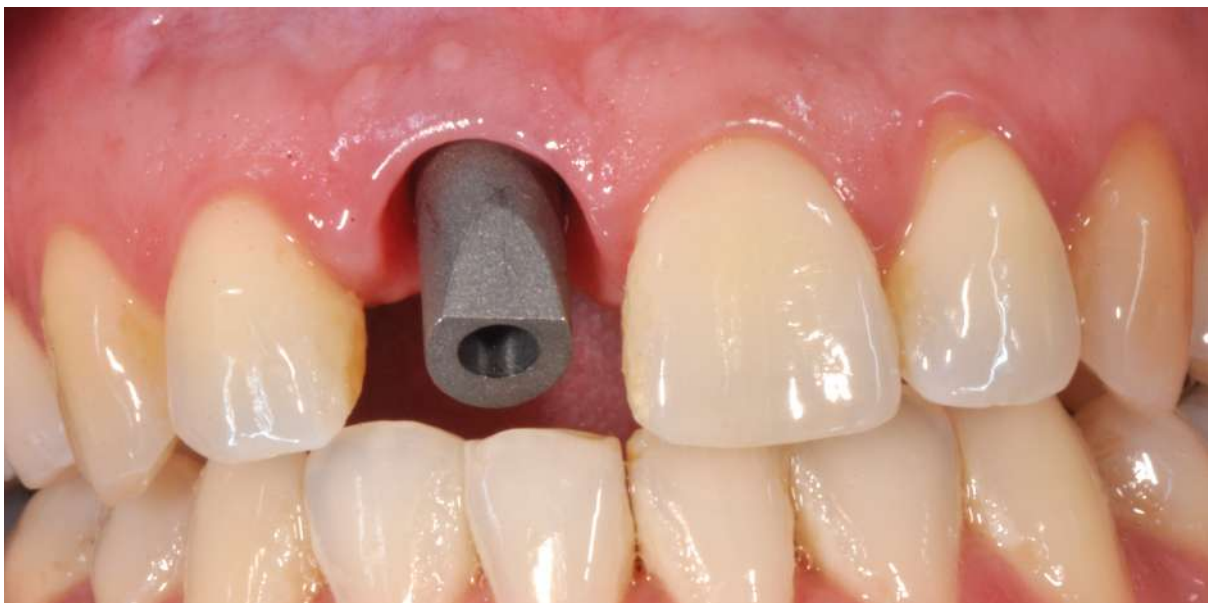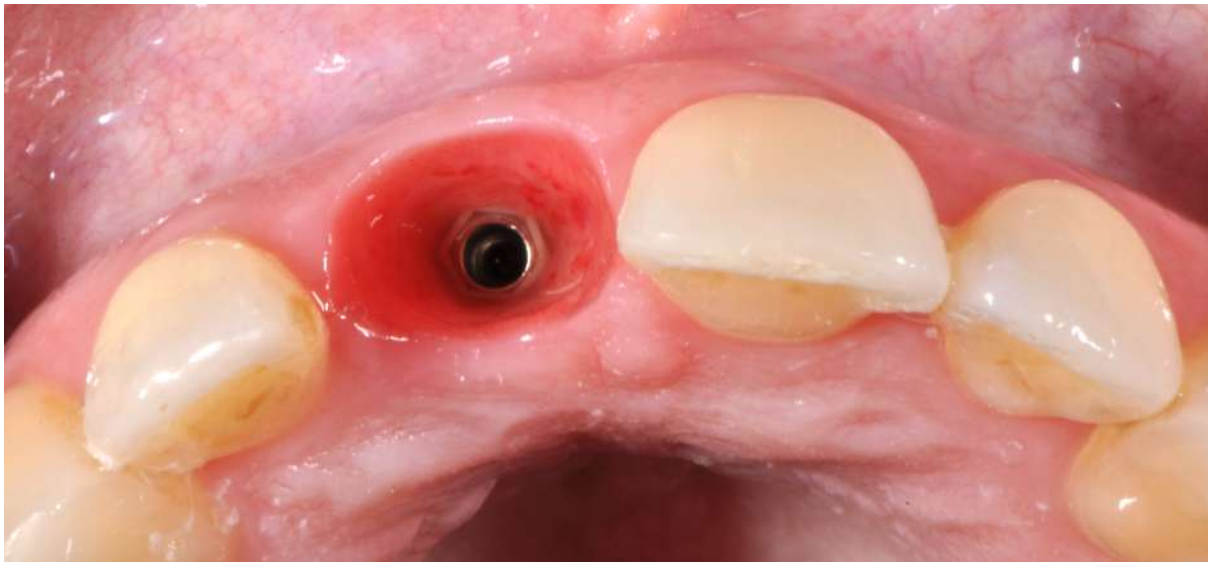
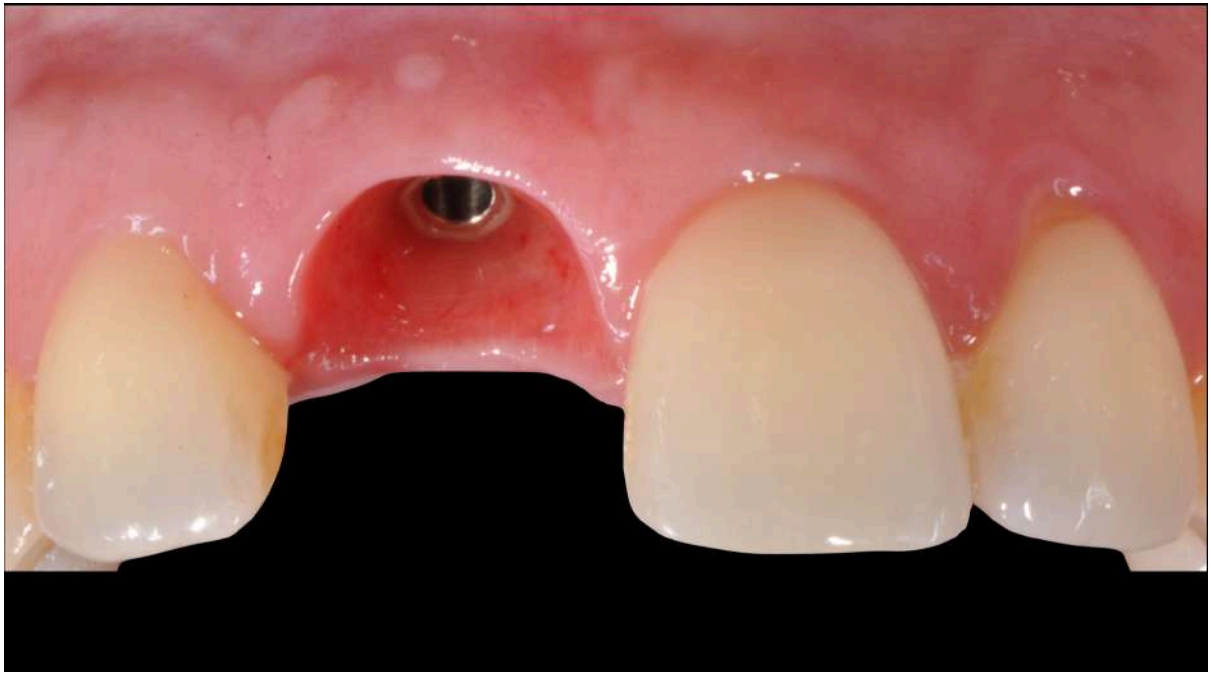
Impression with Intraoral Digital Scanner (Cerec - Sirona)

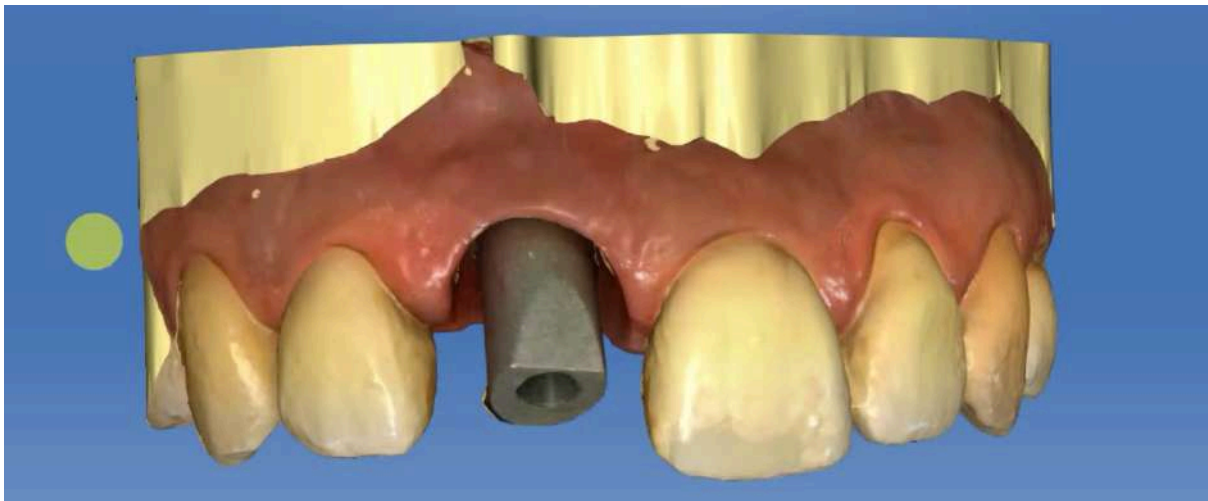










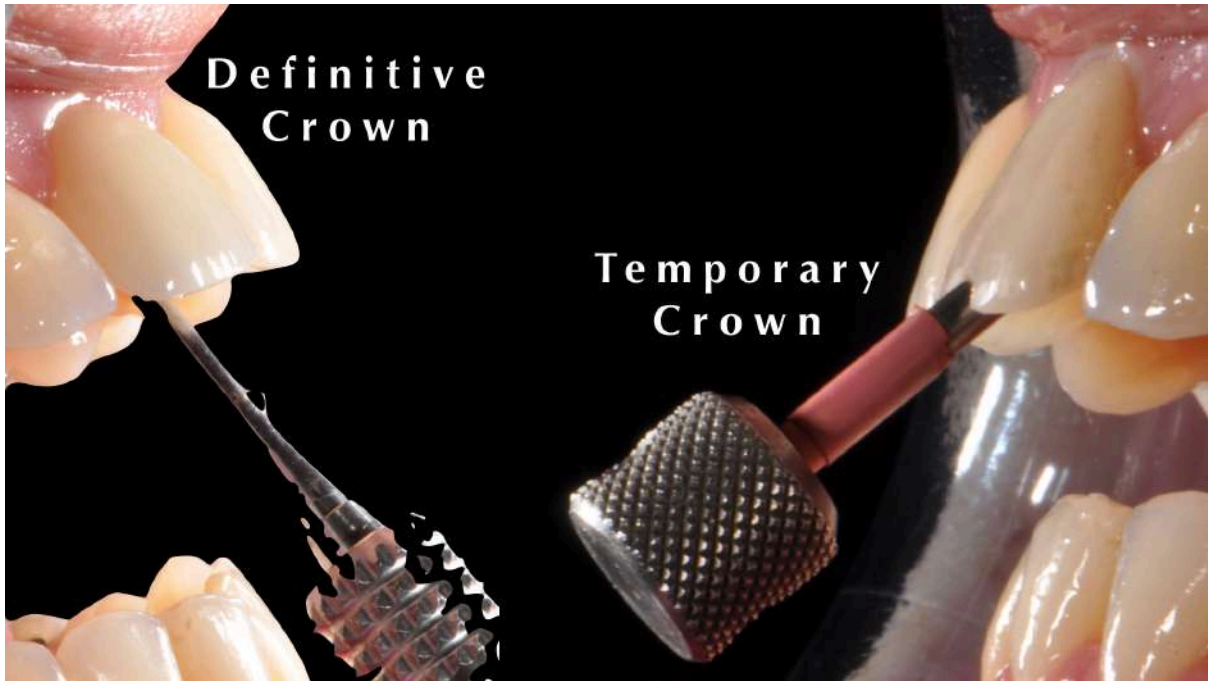

**SPECTRO  
PHOTOMETER**

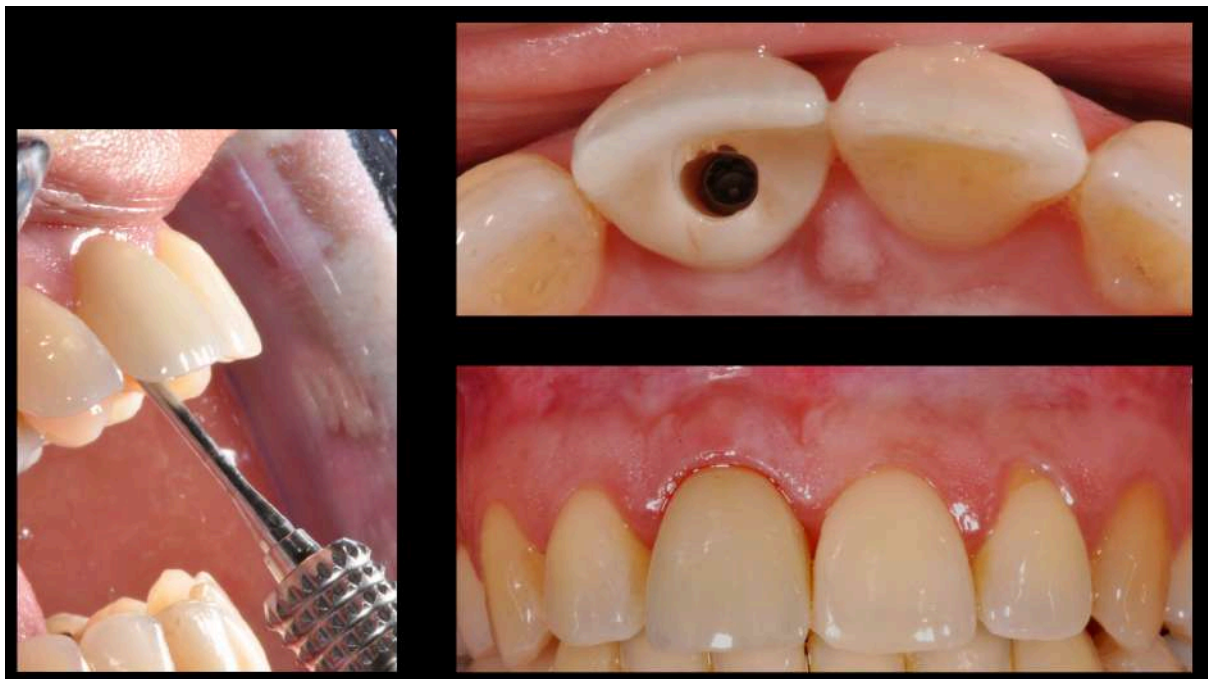
A1	C3
A2	C4
A3	D2
A3.5	D3
A4	D4
B1	
B2	
B3	
B4	
C1	
C2	

**Screwed  
ZIRCONIA Crown**

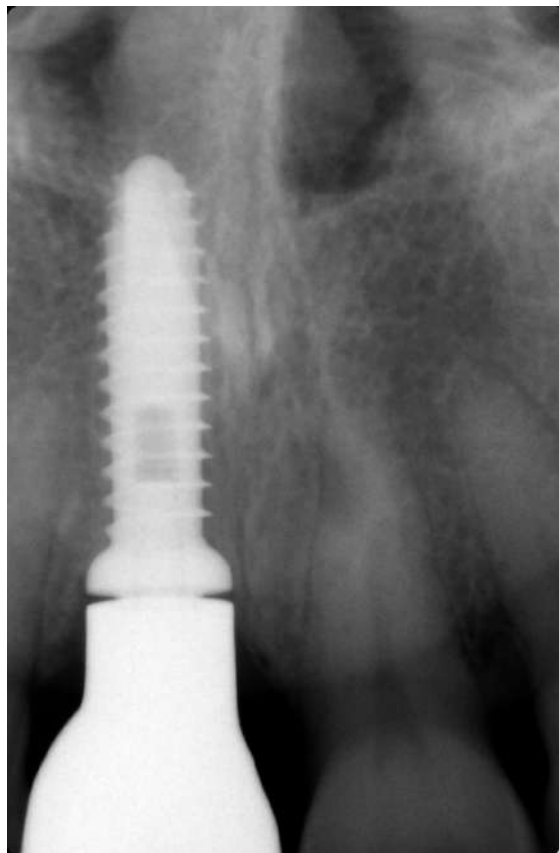
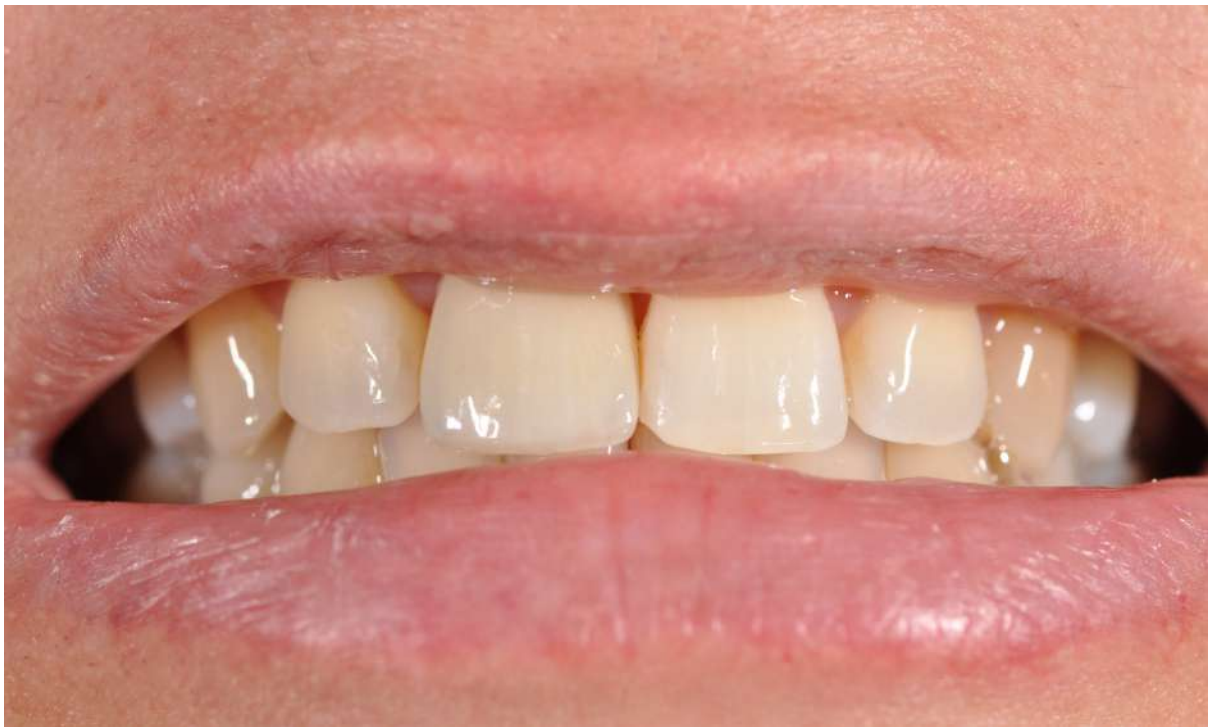**CARDAN  
Screwdriver**



The difference between the temporary and the definitive crown. In the zirconium ceramic definitive crown was used a cardan screwdriver to make a screwed crown.







Follow up at 6 Months

